



ΤΜΗΜΑ ΙΑΤΡΙΚΗΣ
ΣΧΟΛΗ ΕΠΙΣΤΗΜΩΝ ΥΓΕΙΑΣ
ΠΑΝΕΠΙΣΤΗΜΙΟ ΘΕΣΣΑΛΙΑΣ
ΠΡΟΓΡΑΜΜΑ ΜΕΤΑΠΤΥΧΙΑΚΩΝ ΣΠΟΥΔΩΝ
ΥΠΕΡΗΧΟΓΡΑΦΙΚΗ ΛΕΙΤΟΥΡΓΙΚΗ ΑΠΕΙΚΟΝΙΣΗ ΓΙΑ
ΤΗΝ ΠΡΟΛΗΨΗ ΚΑΙ ΔΙΑΓΝΩΣΗ ΤΩΝ ΑΓΓΕΙΑΚΩΝ ΠΑΘΗΣΕΩΝ



Μεταπτυχιακή Διπλωματική Εργασία

" Η χρήση του διαοισοφάγειου υπερήχου στα οξέα αορτικά σύνδρομα: ενδείξεις, αρχές, διάγνωση και σύγκριση με την κλασική διεγχειρητική αγγειογραφία κατά την ενδαγγειακή αποκατάσταση παθήσεων της θωρακικής αορτής"

υπό

Πετρούλα Νανά

Ειδικευόμενη Αγγειοχειρουργικής

Υπεβλήθη για την εκπλήρωση μέρους των

απαιτήσεων για την απόκτηση του

Μεταπτυχιακού Διπλώματος Ειδίκευσης

«Υπερηχογραφική Λειτουργική Απεικόνιση για την πρόληψη & διάγνωση των αγγειακών παθήσεων»

Λάρισα, 2020

Επιβλέπων:

Επαμεινώνδας Ζακυνθινός, Καθηγητής Εντατικής Θεραπείας, Τμήμα Ιατρικής,
Πανεπιστήμιο Θεσσαλίας

Τριμελής Συμβουλευτική Επιτροπή:

Καθ. Ε. Ζακυνθινός

Καθ. Μ. Ματσάγκας

Καθ. Α. Γιαννούκας

Αναπληρωματικό μέλος:

**“The use of trans-esophageal echocardiography in the acute aortic syndromes:
indications, principals, diagnosis and comparison to standard angiography
during endovascular procedures”**

ΕΥΧΑΡΙΣΤΙΕΣ

Στ

Στον καθηγητή Αγγειοχειρουργικής κ. Γιαννούκα & τον Επικ. Καθηγητή Αγγειοχειρουργικής κ. Γ.

Κούβελο

Στον καθηγητή Εντατικής Θεραπείας κ. Ε. Ζακυνθινό και την επιμελήτρια της Μονάδος Εντατικής

Θεραπείας κα. Β. Τσολάκη

Στον επιμελητή της Νευροχειρουργικής Κλινικής κ. Α.Μπρότη

Περίληψη

Εισαγωγή και Σκοπός: Τα οξέα αορτικά σύνδρομα είναι ένα φάσμα απειλητικών για τη ζωή παθήσεων της αορτής. Ταυτόχρονα, η ευρεία χρήση της ενδαγγειακής αποκατάστασης αυτών έχει βελτιώσει τα μετεγχειρητικά αποτελέσματα. Η παρούσα μετα-ανάλυση στόχο έχει να διερευνήσει τη χρησιμότητα της διεγχειρητικής χρήσης του διαοισοφάγειου υπερήχου και να τη συγκρίνει με την κλασική αγγειογραφία κατά τη διενέργεια ενδαγγειακής αποκατάστασης της θωρακικής αορτής.

Μέθοδος: Η παρούσα μετα-ανάλυση συντάχθηκε βάσει των οδηγιών PRISMA και καταχωρήθηκε στη Διεθνή Προοπτική Βάση Καταχώρησης Συστηματικών Ανασκοπήσεων (PROSPERO). Η αγγλική βιβλιογραφία διερευνήθηκε στις βάσεις PubMed, EMBASE και CENTRAL, μέχρι τον Οκτώβριο του 2019. Η προσέγγιση GRADE χρησιμοποιήθηκε προκειμένου να αξιολογηθεί η ποιότητα των δεδομένων-αποδείξεων και τα αποτελέσματα αυτών συμπεριλαμβάνονται στα καταληκτικά σημεία της μελέτης.

Αποτελέσματα: Η αρχική αναζήτηση περιελάμβανε 297 άρθρα, τα οποία θα μπορούσαν να συμπεριληφθούν. Επτά μελέτες, τελικώς, χρησιμοποιήθηκαν, συμπεριλαμβάνοντας 183 ασθενείς. Όλοι οι ασθενείς υπεβλήθησαν σε ενδαγγειακή αποκατάσταση της θωρακικής αορτής υπό τη χρήση διαοισοφάγειου υπερήχου και αγγειογραφίας. Οι διαχωρισμοί τύπου Β αποτέλεσαν την πιο κοινή υποκείμενη νόσο (63.4%). Κατά την ανάλυση ευαισθησίας και ειδικότητας του διαοισοφάγειου υπερήχου σε σύγκριση με την κλασική αγγειογραφία, ο διαοισοφάγειος υπέρηχος φαίνεται να εμφανίζει υψηλή ευαισθησία στην ανάδειξη του σημείου εισόδου του διαχωρισμού (83-99%), στην ασφαλή εισαγωγή του οδηγού σύρματος (96.9%), στην ατελή έκπτυξη του ενδομοσχεύματος (92-94%), και την ανάδειξη πρώιμων

ενδοδιαφυγών (87.7%). Η ειδικότητα ήταν εξαιρετικά χαμηλή, πλην της ανάδειξης των ενδοδιαφυγών όπου εκτιμάται στο 76%.

Συμπέρασμα: Ο διαοισοφάγειος υπέρηχος ίσως αποτελεί ένα χρήσιμο εργαλείο κατά τη διάρκεια της ενδαγγειακής αποκατάστασης της θωρακικής αορτής καθώς παρέχει σημαντικές πληροφορίες τόσο για τα ανατομικά χαρακτηριστικά όσο και για την έκπτυξη του ενδομοσχεύματος και την παρουσία ενδοδιαφυγών. Η χαμηλή ειδικότητα δεν πρέπει να παραβλεφθεί, καθώς φαίνεται πως δε δύναται να αντικαταστήσει την κλασική αγγειογραφία αλλά ίσως παρέχει συμπληρωματικές προς αυτήν πληροφορίες, που επηρεάζουν την κλινική απόφαση και το αποτέλεσμα.

Λέξεις-Κλειδιά: Διαοισοφάγειος υπέρηχος, ενδαγγειακή αποκατάσταση θωρακικής αορτής, οξέα αορτικά σύνδρομα

Abstract

Background & Aim: Acute aortic syndromes (AAS) are a spectrum of life-threatening conditions affecting the aorta. Simultaneously, the widespread use of the endovascular repair (TEVAR) has affected beneficially the post-operative outcomes. The present meta-analysis was designed to investigate the use of the intra-operative use of TEE in comparison to standard angiography in patients undergoing TEVAR.

Methods: The present meta-analysis was conducted using the Preferred Reporting Items for Systematic Reviews and Meta-Analysis statement (PRISMA) guidelines and it has been registered in the International Prospective Register of Systematic Reviews (PROSPERO). A data search of the English medical literature was conducted, using PubMed, EMBASE and CENTRAL databases, until October 31, 2019. The pooled sensitivity and specificity were estimated by the bivariate approach. The GRADE approach was used to evaluate the quality of evidence assessment and the summary of findings for each of the included outcomes.

Results: The initial search identified 297 articles potentially suitable for inclusion. The final analysis included 7 articles (183 patients). All patients underwent TEVAR using TEE and standard angiography intra-operatively. Type B aortic dissection was the commonest underlying lesion in 63.4%. In the sensitivity and specificity analysis of TEE, compared to angiography, as the standard method of intra-operative imaging, TEE seems to be sensitive in the detection of the main entry point or new entry points (83-99%), guidewire advancement into the true lumen (96.9%), graft incomplete deployment (92-94%) and detection of early endoleaks (87.7%). The specificity was low in all parameters, except endoleaks detection (76%).

Conclusion: TEE may be a useful tool during TEVAR, as it provides important information concerning not only the specific anatomical characteristics but graft

deployment and early endoleaks too. The low specificity rate should be acknowledged, as TEE cannot replace standard angiography but may provide additional information which may affect decision making and patients' outcomes.

Key words: Trans-esophageal echocardiography, Endovascular thoracic aorta repair, Acute aortic syndromes

Πίνακας Περιεχομένων

Κεφάλαιο 1 Acute aortic syndromes	10-12
Κεφάλαιο 2 Main disciplines of the trans-esophageal echocardiography	12-18
2.1 Indications for TEE	12-13
2.2 Contra-indications to perform TEE	13
2.3 Management of Patient Sedation	13-14
2.4 Probe insertion and manipulation	14
2.5 Aortic views	15-16
Κεφάλαιο 3 Echocardiography and AAS	16-18
Κεφάλαιο 4 The role of TEE in the diagnostic approach of AAS	18-21
4.1 The role of TEE in aortic dissection diagnosis	18-19
4.2 Effect of TEE in patients' survival	20
4.3 Transesophageal echocardiography and PAU/IMH	20-21
5. Specific issues	22-30
Trans-esophageal echocardiography compared to standard angiography during endovascular procedures for thoracic aorta diseases: review and meta-analysis	
5.1 Introduction	22
5.2 Methods	22-23
5.2.1 Eligibility criteria	22-23
5.2.1 Search strategy	23
5.2.3 Data extraction	23-24
5.2.4 Quality assessment	24-25
5.2.5 Statistical analysis	25
5.3 Results	25-27
5.4 Discussion	27-30
5.5 Conclusion	29-30
References	31-42

Acute aortic syndromes

Acute aortic syndromes (AAS) are all pathologies included in a spectrum of life-threatening conditions of the aorta which are generally characterized by the disruption of medial aortic wall layer.¹ Aortic dissection, intramural hematoma (IMH) and penetrating aortic ulcer (PAU) are three interrelated diseases which have high mortality and morbidity consequences and their early diagnosis and management is mandatory for the survival of the patient.¹ The incidence of AAS has remained stable the last 25 years while the associated early and late mortality have not changed dramatically, despite the technological evolution and the well-established guidelines.^{2,3}

Aortic dissection is classified according to the anatomical location of the entry point into type A and B (Stanford classification). The level of the dissection in correlation to the left subclavian artery (LSA) characterizes the type of dissection; type A are all lesions above the LSA and type B all dissections below this level. In the OXVASC study population which includes all individuals registered to more than 100 general practitioners in Oxfordshire (United Kingdom) 52 aortic dissection events have been recorded (6/100.000). Of the 52 lesions, 71.2% were type A and the remaining type B.⁴ Hypertension was the commonest risk factor, recorded in 67% of patients, followed by tobacco use in 61.5%.⁴ In Europe, the incidence of acute aortic dissections is estimated at 2.53/100.000/year, while type A dissections are recorded in the two thirds of these patients, with a high mortality rate, as half of them die during the early post-dissection period.⁵ A Swedish prospective analysis reported an incidence of acute aortic dissection of 15 per 100.000/year.⁶ Type B aortic dissection had an increasing incidence between 2.9 to 4.0 per 100.000 persons/ year, while males were in higher risk.³

Aortic dissection is the commonest and most fatal of the AAS.⁷ Mortality rate is as high as 1% per hour in the acute phase of untreated type A aortic dissection and more than 70% of patients will die within the first 14 days.⁷ Type B dissection is less life-threatening but the mortality is still significant achieving the 70% in the higher-risk group of patients that need intervention during the acute phase of the dissection (within the first 14 days).⁷ As higher risk patients are characterized the cases where a surgical or endovascular approach is needed due to mal-perfusion and end organ ischemia.⁸

The International Registry of Acute Aortic Dissection (IRAD) has precisely described the clinical characteristics of the aortic dissection.⁸ Different clinical symptoms may be present.⁸ However, the sudden onset of severe sharp pain is the commonest complaint in the majority of patients (90%) while aortic regurgitation and pulse deficit are present in the one third and 15% of patients, respectively.^{8,9} Pain location includes chest with irradiation to the neck, jaw or thoracic or lumbar back as well as abdomen.⁹ Furthermore, nausea, diaphoresis, diarrhea and extreme apprehension may also be present.⁹ Syncope and neurological deficits as paraplegia and paresis may be recorded in a more limited percentage of patients (17 and 9%, respectively) while a combination of them and thoracic pain may be strongly pathognomonic.^{7,9}

Hypertension is common in patients suffering from aortic dissection. However, hemodynamic instability with low pressure may also be present at diagnosis, especially in case of associated aortic rupture or cardiac tamponade.^{7,9} Blood pressure differential between upper or lower extremities and/or pulse deficit may also be detected in case of extension of dissection to the subclavian and iliac

arteries.⁹ Heart diastolic murmur and typical thoracic pain with ischemic electrocardiographic alterations may be present in aortic valve insufficiency and coronary arteries dissection, respectively.⁹ A proximal extension to the carotid arteries may affect central nervous system. The spectrum of neurologic deficits may include weakness up to coma.⁹ Acute kidney injury, colonic and lower limb ischemia may be recorded in renal, mesenteric or iliac arteries dissection.⁹

The incidence of PAU and IMH remain unclear, but in any case, it is increasing through years maybe due to the advanced imaging modalities which permit diagnosis in asymptomatic patients.³ The prevalence of PAU between patients with AAS is estimated between 2.3 and 7.6% and they are generally localized in the majority of cases at the descending aorta (90%).¹⁰ Additionally, IMH, which is a related to PAU lesion, accounts for 5-20% in AAS population and is also localized commonly to the descending aorta (60%).¹¹

Main disciplines of the trans-esophageal echocardiography (TEE)

Indications for TEE

TEE indications are divided into general and specific.¹² Transthoracic echocardiography (TTE) may be less informative in obese patients, patients under mechanical ventilators or unable to move into the left lateral decubitus position and polytrauma with chest wall injuries.¹² In cases where TTE may not be sufficiently diagnostic, such as anatomical abnormalities of the aorta, the evaluation of prosthetic valves, native valve masses and abscesses, and the left atrial appendage, TEE can be used to achieve more sensitivity and specificity.¹²

Specific procedural indications include the guidance of trans-catheter procedures and assessments of cardiac structure and function pre, intra and post-

cardiac and non-cardiac procedures.^{13,14} These specific procedural indications recommended by the American Society of Anesthesiologists and the Society of Cardiovascular Anesthesiologists include the use of TEE in selected cardiac procedures, as valve replacement and coronary artery bypass surgery (CABG), thoracic aortic surgery, and guiding the optimal placement of catheter-based procedures.¹⁴

Contra-indications to perform TEE

Absolute contraindications of the performance of TEE include a history of dysphagia, active esophagus disease or recent operation while relative contraindications are esophageal varices or active upper gastrointestinal bleeding. In the latest group of patients, an evaluation of the risk-to-benefit ratio must be assessed individually for each patient before the intervention.¹⁵

Management of Patient Sedation

Patients that are candidates for TEE are divided into three groups in terms of sedation; awake, ventilated patients in the intensive care unit (ICU) and anesthetized patients undergoing operations. The vast majority of TEE procedures are performed while the patient is sedated, typically using the moderate sedation standard where the patient does not need mechanical ventilation support.¹² Food and beverages restriction for 6 hours pre-TEE is sufficient in these cases.^{12,16} Intravenous access with a 20-gauge catheter is required during TEE and the left arm should be available for contrast injections when a contrast-enhanced TEE is needed.¹² Pre-TEE medical history and clinical examination are mandatory to assess the interventional risk, as patients indicated to undergo TEE are considered high-risk for cardiac and pulmonary

complications.¹² Monitoring, airway equipment and emergency medications should also be available.¹² Patients, hospitalized in the intensive care unit (ICU) or undergoing any surgical procedure (supine position), are already under different types of sedation or anesthesia.¹² As previously reported, TEE is a semi-invasive procedure with well-defined criteria for training and all medical and para-medical staff (doctors providing TEE, anesthesiologists, surgeons and nurses) should be familiar with the procedure.¹⁷ Specific discharge and follow-up instructions are mandatory after the procedure.¹²

Probe insertion and manipulation

Typically, an outpatient is in a left lateral decubitus position, under moderate sedation and the operator stands on the left.¹² Using his fingers or a laryngoscope, the operator inserts the probe into the midline of the pharynx and advances it down to the esophagus. Some patients will not tolerate the probe and may need further anesthetic support.¹² In cases under general anesthesia, probe insertion needs further manipulation with jaw thrust and ante-flexion of the probe.¹²

The echocardiographer has to keep in mind the probe to be oriented, having the heart as the reference point.¹⁸ Then:

- a. The probe is advanced, with no excessive flexion, to prevent esophagus trauma, distally to the esophagus or stomach and withdrawn upwards
- b. The probe is turned clockwise or counterclockwise within the esophagus to the right and left side, respectively
- c. The probe is rotated into 4 directions, using the two control wheels (the large for anterior-posterior axis and the small one for the right-left axis)
- d. The imaging plane can be directed axially between 0 and 180 degrees.¹⁸

Aortic views

Many details could be provided concerning the heart imaging under trans-esophageal echocardiography. However, this information would overcome the purpose of the current analysis which concerns the use of TEE in aortic syndromes. The current literature offers many data for the expertized or someone interested in TEE.¹²⁻¹⁸

Ascending aorta

A backward rotation between 90 and 110 degrees with simultaneous withdrawal of the probe can provide long axis view of the proximal ascending aorta while the pulmonary artery lies posteriorly. Pulling backwards the transducer and using a rotation between 0 and 30 degrees, short axis of the ascending aorta view can be provided. The superior vena cava, the main and right lobar pulmonary artery can also be seen. Pulsed and continuous wave and color Doppler may be useful in the detection of different pathologies.¹²

Descending aorta

The transducer angle is rotated within 0 and 10 degrees and the probe is turned to the left. Distal descending aorta at the level of visceral arteries may not be easily seen due to the presence of abdominal gas and its variable position. Pulling the probe above the diaphragm provides better information about the condition of the descending aorta. The short axis view is obtained at an angle ranging between 0 and 10 degrees while a long axis view needs further rotation between 90 to 100 degrees.¹²

While the aorta is in the center of the image, depth should be decreased and gain should be adjusted and then, the probe is advanced or withdrawn in order to

evaluate the total length of the descending aorta. Providing details about the location of different lesions in the descending aorta may be challenging as no landmarks are available. Intercostal arteries and the hemi-azygous vein may also be detected in the descending aorta assessment.¹² Furthermore, the numerical record on the probe may help detect the lesion by calculating the distance from the teeth. Color or pulsed Doppler may provide further information concerning the anatomical characteristics and enforce differential diagnosis in normal anatomical structures and pathological lesions.¹²

Aortic arch

From the short axis view of the descending aorta, withdrawing the probe may image left subclavian artery.¹² At this location, a turn of the probe to the right helps achieving a long axis view of the middle portion of the aortic arch while the presence of left main bronchus may hamper the visualization of the proximal and distal arch.¹² In addition to the aorta, the left innominate vein is frequently imaged by color Doppler. The pulmonary artery and vein may be seen in the long axis view after depth adjustment.¹²

Echocardiography and AAS

As the main symptom of the AAS is the thoracic pain, transthoracic (TTE) and transesophageal echocardiography (TEE) are useful as the initial urgent imaging approach during differential diagnosis in the emergency department.¹ Current guidelines suggest computed tomography angiography (CTA) as the standard imaging for the diagnosis of AAS with a IIa C level of evidence³

TEE is considered as one of the optimal imaging techniques for AAS.^{1,19,20} The absence of soft tissue structures and bones between the aorta and the esophagus allows high quality imaging and permits the identification of the main and secondary entry points, the intimal flap, the compression of the true lumen and the dynamic flow pattern of false lumen, in most cases of aortic dissection, with a sensitivity and specificity rate more than 85%.^{1,21-23} Furthermore, echocardiography provides additional information for the operational planning and may be used intra-operatively.¹

An incidence of complications up to 2.8% has been reported in a 6-year Mayo experience period.¹⁵ In terms of peri-interventional complications, they are mainly gastrointestinal, cardiovascular and respiratory and may be related to probe insertion, procedure and sedation.^{24,25} They include infection, allergic drug reaction and ultrasound cavitation.²⁴ Only isolated cases of aortic rupture have been recorded and probably, they are associated with the underlying disease than the procedure.¹ Despite its low complication rate, they should be acknowledged while meticulous peri-interventional measures, as blood pressure control, are mandatory for their prevention.²⁴

The main limitations of the technique are its semi-invasive nature, needing for appropriate sedation, the blind area hampering the clear visualization of the distal descending aorta and innominate artery and the presence of artifacts.^{1,26} An intimal flap imitation may be presented in almost half of cases (45-55%) due to linear reverberation images; however without distracting the results of the intervention when performed by an experienced echocardiographer.¹ Artifacts may be detected in the aortic root and the medial ascending aorta due to reverberation from the anterior wall

of the left atrium and the posterior wall of the right pulmonary artery, respectively.¹ M-mode echocardiography is the best way to differentiate artifacts from real intimal flap.¹

The role of TEE in the diagnostic approach of AAS

The role of TEE in aortic dissection diagnosis

The standard of, by the current guidelines and according to further literature, is CTA.³ It is remarkable that more than half of patients undergo CTA as the initial diagnostic imaging.^{3,8} Three-dimensional reconstruction may offer valuable information for the underlying anatomical characteristics and the pre-operative planning.⁷ This imaging modality is quick, widely available, operator independent with a diagnostic accuracy of near 100%.²⁷ CTA includes the entire aorta, identifying all interesting characteristics of intimal flap, site of intimal tear, dissection extent, aortic dimensions, false lumen anatomy, branch involvement and associated pericardial or pleural effusions.²⁷

Magnetic resonance imaging (MRI) is also useful and may replace CTA in future years.⁷ MRI is safe and contrast-free and may emerge as a comprehensive standard approach in the pre-operative design.²⁸ In a meta-analysis of all used imaging modalities, including TEE, CTA and MRI, the pooled sensitivity (98%-100%) and specificity (95%-98%) were comparable between the techniques while the positive likelihood ratio seemed higher for MRI.²⁹ The analysis concluded that all modalities were equally reliable in dissection diagnosis; a finding which is in accordance to previous studies.^{29,30}

TEE, as mentioned previously is a semi-invasive diagnostic tool which may help differential diagnosis in suspected aortic dissection.²⁸ Multiplane and biplane TEE have excellent accuracies in the evaluation of aortic dissection and their anatomical characteristics and may be identical as a pre-operative imaging for type A dissections.³¹ The specificity and sensitivity of TEE for the detection of present or absent aortic dissection achieves 100%.³¹ In a retrospective comparative study (TEE vs TTE), TEE permitted the detailed detection of the anatomical characteristics as diameter, entry point, intimal flap, true and false lumens, branches and descending aorta involvement, hematoma expansion and aortic fissuration as well as further information concerning heart function including tamponade, valvular insufficiency, left ventricle contractile function.³² Especially, concerning coronary involvement, TEE may successfully detect its presence in the pre-operative setting and reduce events of unclear coronary involvement in comparison to CTA.³³ In any case, diagnosis may be barked by the air-filled trachea and main bronchi while an association of TEE and aortography enforces the diagnostic accuracy in type A dissection.^{34,35}

In type B aortic dissection, the role of TEE is important in the detection of extension to the proximal aorta, presence of pericardial and pleural effusions. TEE detects the main entry point with a sensitivity as high as 100% and may be helpful when planning an open surgical repair.³⁶ Despite that, in case of distal abdominal aorta involvement, extreme tortuosity or kinking and previous endovascular or open aortic repair may reduce the interpretation of the modality.³⁶ TEE may have an important effect on decision making and give precise intra-operative information not only in terms of heart function but further anatomical or technical details.³⁶

Effect of TEE in patients' survival

Emergent aortic dissection management using TEE may positively affect preoperative mortality.³⁷ Interestingly, the routine use of TEE during the management of aortic dissection may have a positive impact on hospitalization duration and a fundamental in-hospital mortality decrease from 43 to 17.3% due to its high sensitivity in dissection specific features that may lead to a better choice of intervention.³² The Spanish Registry of Acute Aortic Syndrome, which evaluated 629 consecutive patients with acute aortic syndrome (443 type A and 186 type B) concluded that advances in diagnostic modalities of aortic dissection may significantly reduce the associated mortality.²⁵ In the post-operative follow-up, as repetitivity of the method is safe and effective, important information may be obtained related to the evolution of false lumen thrombosis, aortic diameter alterations and aortic valve function.³² The detection of post-operative complications may have an impact on long-term prognosis.³²

Transesophageal echocardiography and PAU/IMH

PAU and IMH are atypical forms of aortic dissection, presenting with a symptomatology analogous to typical forms of dissection.³⁸ Considering the differential diagnosis of IMH, a non-communicating dissection with thrombosed false lumen may hamper correct diagnosis.^{39,40,41} Health providers should have in mind that IMH is more common in descending than ascending aorta, while proximal IMH may be 4 times more lethal than distal IMH.^{8,42} Different mechanisms are proposed to provoke IMH which may be associated with ruptured vasa vasora and intramural hemorrhage.⁴³ A sudden thoracic or back pain, especially in elder patients with

systematic atherosclerosis and hypertension, should raise the clinical suspicion of PAU.^{41,44}

As in dissection cases, current imaging modalities permit safe diagnosis of PAU and IMH with a high degree of accuracy.⁴⁴ CTA is the standard imaging approach for PAU and IMH detection with specificity estimated at 87–100% and sensitivity of 83–94%.^{3,45} However, MRI and TEE may provide important information.³⁸ TEE assessment in patients with PAU may be used in the diagnostic criteria and help differentiation from standard dissection and IMH.³⁸ MRI appears very efficient with sensitivity and specificity of 95-100%.⁴⁵

TEE may detect these lesions and their complications safely in the majority of patients. PAU may be present as a focal outpouching of the aortic wall while IMH may be detected as a localized thickening of the wall with a “thrombus-like appearance”.^{41,43} Sensitivity of TEE reaches 100% and specificity 91% in this group of patients; the differential diagnosis from dissection, with false lumen thrombosis, may be difficult and affect the specificity performance of the technique.^{43,46} Along with this, IMH may present specific characteristics which confirm diagnosis; including wall thickening of the involved segment of more than 7mm (which may be greater in the descending aorta), compression of the aortic lumen and echolucent areas in the aortic wall (described in 70-80% of patients with IMH).^{47,48} In case of IMH, intima covers the surface of the hematoma and is separated from the media layer, creating the echolucent area detected in TEE, which may affect prognosis but is not associated with dissection evolution.^{48,49}

Specific issues

Trans-esophageal echocardiography compared to standard angiography during endovascular procedures for thoracic aorta diseases: review and meta-analysis

Introduction

The widespread use of the endovascular repair of the thoracic aorta (TEVAR) has affected beneficially the post-operative morbidity and mortality rates, even in the acute setting.^{50,51} High-quality angiographic imaging during TEVAR is mandatory and specific equipment as hybrid and angiographic suites appear as the optimal solution.⁵² Despite that there are no recommendations suggesting the intra-operative TEE evaluation, current literature has shown that TEE may be a very useful tool during TEVAR.⁵³

Meticulous imaging is mandatory for the immediate diagnosis and careful pre-operative planning and treatment in aortic diseases.⁵⁴ Transthoracic and transesophageal echocardiography (TEE) are useful in the identification of the underlying pathology, the indication of emergent treatment and the decision making concerning the surgical technique as well as intra-operative patient's close heart monitoring.^{3,54,55}

The present meta-analysis was designed to compare the intra-operative use of TEE to standard angiography in patients undergoing TEVAR.

Methods

Eligibility criteria

The present meta-analysis was conducted using the Preferred Reporting Items for Systematic Reviews and Meta-Analysis statement (PRISMA) guidelines.⁵⁶ We focused on observational and case series studies. In addition, we discarded editorials, reviews and meta-analyses, underpowered studies (< 5 patients), and studies focusing on different ultrasonography methods.

Search strategy

A data search of the English medical literature was conducted, using PubMed, EMBASE and CENTRAL databases, until September 31, 2019. The P.I.C.O. (patient; intervention; comparison; outcome) model was used to define the clinical questions and select relevant articles (**Table II**).⁵⁷ The following search terms including Expanded Medical Subject Headings (MeSH) were used in various combinations: “trans-esophageal echocardiography in TEVAR” and “trans-esophageal echocardiography in thoracic aorta repair”. The primary selection was based on title and abstract. A secondary scrutiny was performed according to the full text.

Data extraction

Data extraction was performed by 2 independent reviewers (P.N., G.K.) using a non-blinded standardized form and any discrepancies were resolved by consensus or by consulting a third reviewer (V.T.). No patients were involved in the conduction of the meta-analysis and no informed consent or institutional review board approval was required. Studies considered for inclusion and full text review fulfilled the following criteria: (1) to report on patients treated with TEVAR for aortic pathologies under TEE and angiography (2) to include technical and operational data presented by the

two methods, (3) to provide completion angiographic and TEE findings as graft deployment and presence of endoleak and (4) at least 3 studies were needed to extract meta-analytic outcomes.

A standardized data extraction Microsoft Excel file was developed. Data were retrieved from the text or tables. Extracted data included study characteristics such as author and date of publication. Furthermore, the following information was collected: baseline demographics (age, sex), type of underlying aortic disease, guidewire advancement, true lumen detection, and false lumen thrombosis or sac exclusion according to the underlying disease, graft deployment and presence of endoleak.

Quality assessment

The GRADE approach was used to evaluate the quality of evidence assessment and the summary of findings for each of the included outcomes, to ensure that the effectuated judgments are systematic and transparent. The standard model for the evidence profile incorporates: a) a list of the outcomes, b) the number and design of included studies, c) judgements about each of the quality of evidence factors; risk of bias, inconsistency, indirectness, imprecision, other considerations (including publication bias and factors that affect the quality of evidence), d) the assumed risk; a measure of the typical burden of the outcomes, i.e. illustrative risk or also called baseline risk, baseline score, or control group risk, e) the corresponding risk; a measure of the burden of the outcomes after the intervention applied, f) the relative effect; for dichotomous outcomes the table will usually provide risk ratio, odds ratio, or hazard ratio, g) the absolute effect; for dichotomous outcomes the number of fewer or more events in treated group, compared to the control group, h) the rating of the overall quality of evidence for each outcome, j) classification of the importance of

each outcome and k) footnotes.⁵⁸ **Table III** summarizes the results of the evidence quality assessment using the GRADE approach while **Table IV** represents a summary of evidence table.

Statistical analysis

Initially, we quantified the inter-study heterogeneity using the Higgins I^2 estimate. Then, we estimated the pooled sensitivity and specificity, along with the 95% CIs, according to a bivariate approach in anticipation of a positive correlation between the sensitivity and the false positive rate, and the results were plotted on SROC curves.⁵⁹ Significance was set at $p < 0.05$, and we used continuity correction equal to 0.5 for metrics associated with zero events. The robustness of the findings was tested by re-analyzing the results after the exclusion of the studies with zero events. Publication bias was eyeballed by trim-and-fill funnel plots. All statistical analyses were executed by the R-statistical environment.

Results

The initial search identified 297 articles potentially suitable for inclusion. After exclusion of articles whose titles and abstracts had no relevance to the topic, the full texts of 49 articles were retrieved and assessed for eligibility. The final analysis included 7 studies published between 1999 and 2015, which included a total of 183 patients (**Figure I**). The study cohorts ranged from 5 to 44 patients. All studies were observational cohort studies; 2 retrospective and 5 prospective.

All patients underwent TEVAR using TEE and standard angiography intra-operatively. Males were 53% and the mean age was estimated at 59 years (range 48-67 years). All patients were treated using endovascular means for a variety of aortic

lesions. Type B aortic dissection was the commonest underlying lesion in 63.4% of patients (116/183), followed by thoracic aneurysms (TAAs) in 22.4% (41/183), previous aortic trauma in 4.3% and pseudo-aneurysm in 3.7% of patients (6/183). PAU and IMH, as expected, were rarer and described only in 4.9% of cases (2.7% and 2.2%, respectively). The remaining patients suffered from 2 thoraco-abdominal aneurysms and 1 ruptured TAA. In 6 out of 7 studies,⁶⁰⁻⁶⁵ both urgent and elective cases were described while only in one study all patients (12 cases) were treated for acute type B aortic dissection.⁶⁶

In all studies, standard angiography and TEE were used intra-operatively while in two; a further comparison was accomplished between the previous methods and intra-vascular ultrasound (IVUS) and contrast TEE, respectively.^{64,65} In pre-operative setting, 11 patients underwent TEE^{60,62} while in 3 studies, including 118 cases, CTA and MRI were used for diagnosis.^{61,63,65} In 2 studies, the diagnostic imaging method was not reported.^{64,66} In 4 studies,^{62,63,65,66} the post-operative evaluation of patients was accomplished using CTA while in the remaining, no post-operative data are reported.

In the sensitivity and specificity analysis of TEE, compared to angiography, as the standard method of intra-operative imaging, TEE seems to be sensitive in the detection of entry points, guidewire and graft deployment, as well as, early post-operative endoleaks. Concerning the detection of the main entry point or new entry points after the insertion of the endograft, 2 studies have been included in the analysis (**Figure II**).^{63,64} Sensitivity ranges between 83-99% while specificity between 5-8%. Furthermore, guidewire advancement into the true lumen had a sensitivity at 96.9% and a specificity of only 12.9% (**Figure III**).^{61,63-65}

TEE could detect early endograft incomplete deployment during TEVAR procedures.^{64,65} TEE sensitivity remains highly acceptable (92-94%) while specificity is low (4-6%), as presented in **Figure IV**. Intra-operative detection of endoleaks may be achievable with TEE. Sensitivity is estimated at 87.7% while specificity at 76% (**Figure V**) which is the highest specificity rate in TEE approach intra-operatively between the features studied in this analysis. Six out of seven studies were included in this analysis.^{60,62,63,64,65,66} The detection of endoleaks has affected the final medical decision, concerning further balloon inflation and graft implantation. In 34 patients, TEE has set the indication for additional balloon inflation while 34 stents were used as extension of the initial endografts to resolve endoleaks detection.⁶²⁻⁶⁶ The intra-operative complication rate which was associated with the use of TEE was 0%.⁶¹⁻⁶⁶

Discussion

TEE may have a crucial role during the surgical monitoring, the detection of intra-operative complications, such as guidewire advancement into the false lumen, incomplete graft deployment and sealing and should be accomplished immediately post-operatively.⁶⁷ Previous studies have highlighted the role of TEE in the detailed detection of aortic lesions which may affect decision making and alternate the pre-operative planning.⁶⁷ However, the semi-invasive character of the procedure may hamper the wider use of TEE in all patients.³ In current European guidelines, TEE is a second line option in the diagnostic approach of thoracic aorta diseases while there are no recommendations concerning the intra-operative use of TEE during TEVAR.³

Remarkably, TEE had a high sensitivity in all analyses of this study, including guidewire advancement in to the false lumen, incomplete graft deployment, and

endoleak and entry point detection. TEE seems to have a high ability in the recognition of true positive results of angiography. Along this line, TEE enforces the diagnostic accuracy of angiography, especially in terms of guidewire advancement and early endoleak detection, and affects the final surgical decision.⁶²⁻⁶⁶ However, the low specificity rate hampers the diagnostic accuracy of TEE which may overestimate all these intra-operative findings. TEE lacks the capacity to recognize false positive results. Considering all previous remarks, it seems that TEE may have an adjunctive role in TEVAR as it clarifies angiographic findings; without having though the sensitivity needed to substitute the standard imaging.

While endoleaks remain a significant issue in endovascular approaches, the intra-operative detection of them significantly predicts the presence of a postoperative leak, the reduction of sac regression and the higher need of further intervention, especially in cases of type I leaks.⁶⁸ The intra-operative detection of endoleaks is the strongest argument of the intra-operative use TEE with sensitivity estimated at 87.7% and specificity at 76%. Post-operative CTA and contrast enhanced echocardiography findings were in accordance to TEE endoleak detection.^{62,69,70} Furthermore, leak identification may affect intra-operative surgical decisions; in 68 cases of this analysis (39%), the need for further intervention, as balloon inflation and graft deployment, was set by the intra-operative TEE. In 34 patients, additional balloon inflation was performed and in 34 cases, an additional stent-graft was deployed to achieve successful sealing.⁶²⁻⁶⁶

TEE, compared to conventional intra-operative angiography, has a high sensitivity rate in the detection of the main entry point and guidewire advancement into the true lumen. TEE may have an important assistant role in TEVAR procedures by guiding

catheter placement in the descending aorta at an appropriate position; a fact that may affect the post-operative outcomes.^{69,71} TEE may offer detailed information concerning the anatomical aortic characteristics in terms of collaterals of intercostal arteries, in order to preserve flow and spinal cord ischemia.⁶¹ In endografts malposition, TEE may detect incomplete deployment with a high sensitivity but low specificity. TEE permits excellent evaluation of the correct placement of the stent by estimating flow reduction in the false lumen after graft deployment, especially in type-B aortic dissection.^{64,71}

Limitations

This meta-analysis included data across cohort studies to estimate the intra-operative role of TEE during TEVAR procedures. The main limitation of this review is that all articles included were non-randomized observational studies and the methodologic quality of which varied considerably. Furthermore, patients suffered from different types of thoracic pathologies that may need urgent or elective treatment, according to the clinical status of the patients. Technical details concerning the material used, the type of stent, as well as the exact morphological characteristics of the aorta were not available in all studies. The lack of long-term follow-up may hamper further clear conclusions about the role of TEE in TEVAR. The heterogeneity between studies impedes further definite conclusions.

Conclusion

TEE may be a useful tool during TEVAR, as it provides important information concerning not only the specific anatomical characteristics but graft deployment and early endoleaks too. The low specificity rate should be acknowledged, as TEE cannot

replace standard angiography but may provide additional information which may affect decision making and patients' outcomes.

Conflict of interest: None

References

1. Evangelista A, Maldonado G, Gruosso D, Gutiérrez L, Granato C, Villalva N, et al. The current role of echocardiography in acute aortic syndromes. *Echo Res Pract.* 2019;6:R53-R63
2. DeMartino RR, Sen I, Huang Y, Bower TC, Oderich GS, Pochettino A, et al. Population-Based Assessment of the Incidence of Aortic Dissection, Intramural Hematoma, and Penetrating Ulcer, and Its Associated Mortality From 1995 to 2015. *Circ Cardiovasc Qual Outcomes.* 2018;11:e004689.
3. Riambau V, Böckler D, Brunkwall J, Cao P, Chiesa R, Coppi G, et al. Editor's Choice - Management of Descending Thoracic Aorta Diseases: Clinical Practice Guidelines of the European Society for Vascular Surgery (ESVS). *Eur J Vasc Endovasc Surg.* 2017;53:4-52.
4. Howard DPJ, Sideso E, Handa A, Rothwell PM. Incidence, risk factors, outcome and projected future burden of acute aortic dissection. *Ann Cardiothorac Surg.* 2014;3:278-84.
5. Melvinsdottir IH, Lund SH, Agnarsson BA, Sigvaldason K, Gudbjartsson T, Geirsson A. The incidence and mortality of acute thoracic aortic dissection: results from a whole nation study. *Eur J Cardiothorac Surg.* 2016;50:1111-7.
6. Landenhed M, Engstrom G, Gottsater A, Caulfield MP, Hedblad B, Newton-Cheh C, et al. Risk profiles for aortic dissection and ruptured or surgically treated aneurysms: a prospective cohort study. *J AmHeart Assoc* 2015;4:e001513.
7. Practice guidelines for preoperative fasting and the use of pharmacologic agents to reduce the risk of pulmonary aspiration: application to healthy patients undergoing elective procedures: an updated report by the American

- Society of Anesthesiologists Committee on Standards and Practice Parameters.
Anesthesiology 2011;114:495-511
8. Shanewise JS, Cheung AT, Aronson S, Stewart WJ, Weiss RL, Mark JB, et al. ASE/SCA guidelines for performing a comprehensive intraoperative multiplane transesophageal echocardiography examination: recommendations of the American Society of Echocardiography Council for Intraoperative Echocardiography and the Society of Cardiovascular Anesthesiologists Task Force for Certification in Perioperative Transesophageal Echocardiography. J Am Soc Echocardiogr 1999;12:884-900.
 9. Frank J. Criado, Aortic Dissection, A 250-Year Perspective, Tex Heart Inst J. 2011; 38:694-700
 10. Eggebrecht H, Nienaber CA, Neuhauser M, Baumgart D, Kische S, Schmermund A, et al. Endovascular stent graft placement in aortic dissection: a meta-analysis. Eur Heart J 2006;27:489-98.
 11. Evangelista A, Mukherjee D, Mehta RH, O’Gara PT, Fattori R, Cooper JV, et al. Acute intramural hematoma of the aorta: a mystery in evolution. Circulation 2005;111:1063-70.
 12. Hahn RT, Abraham T, Adams MS, Bruce CJ, Glas KE, Lang RM, et al. Guidelines for Performing a Comprehensive Transesophageal Echocardiographic Examination: Recommendations from the American Society of Echocardiography and the Society of Cardiovascular Anesthesiologists. Anesth Analg. 2014;118:21-68.
 13. Reeves ST, Finley AC, Skubas NJ, Swaminathan M, Whitley WS, Glas KE, et al. Basic perioperative transesophageal echocardiography examination: a

- consensus statement of the American Society of Echocardiography and the Society of Cardiovascular Anesthesiologists. *J Am Soc Echocardiogr* 2013;26:443-56.
14. Thys DM, Brooker RF, Cahalan MK, Connis RT, Duke PG, Nickinovich DG, et al. Practice guidelines for perioperative transesophageal echocardiography. An updated report by the American Society of Anesthesiologists and the Society of Cardiovascular Anesthesiologists Task Force on Transesophageal Echocardiography. *Anesthesiology* 2010;112:1084-96
 15. Khandheria B, Seward J, Tajik J. Transesophageal Echocardiography. *Mayo Clin Proc.* 1994;69:856-63.
 16. Apfelbaum JL, Caplan RA, Connis RT, Epstein BS, Nickinovich DG, Warner MA. Practice guidelines for preoperative fasting and the use of pharmacologic agents to reduce the risk of pulmonary aspiration: application to healthy patients undergoing elective procedures: an updated report by the American Society of Anesthesiologists Committee on Standards and Practice Parameters. *Anesthesiology* 2011;114:495-511.
 17. Cahalan MK, Stewart W, Pearlman A, Goldman M, Sears-Rogan P, Abel M, et al. American Society of Echocardiography and Society of Cardiovascular Anesthesiologists task force guidelines for training in perioperative echocardiography. *J Am Soc Echocardiogr* 2002;15:647-52.
 18. Shanewise JS, Cheung AT, Aronson S, Stewart WJ, Weiss RL, Mark JB, et al. ASE/SCA guidelines for performing a comprehensive intraoperative multiplane transesophageal echocardiography examination: recommendations

- of the American Society of Echocardiography Council for Intraoperative Echocardiography and the Society of Cardiovascular Anesthesiologists Task Force for Certification in Perioperative Transesophageal Echocardiography. *J Am Soc Echocardiogr* 1999;12:884-900.
19. Evangelista A, Carro A, Moral S, Teixidó-Turà G, Rodríguez-Palomares JF, Cuéllar H, et al. Imaging modalities for the early diagnosis of acute aortic síndrome. *Nature Reviews: Cardiology*. 2013;10:477-86.
 20. Bhawe NM, Nienaber CA, Clough RE, Eagle KA. Multimodality imaging of thoracic aortic diseases in adults. *JACC: Cardiovascular Imaging* 2018;11:902-19.
 21. Shiga T, Wajima Z, Apfel CC, Inoue T, Ohe Y. Diagnostic accuracy of transesophageal echocardiography, helical computed tomography and magnetic resonance imaging for suspected thoracic aortic dissection. Systematic review and meta-analysis. *Archives of Internal Medicine*. 2006;166:1350-6.
 22. Flachskampf FA, Wouters PF, Edvardsen T, Evangelista A, Habib G, Hoffman P, Hoffman R, Lancellotti P, Pepi M, Donal E. Recommendations for transoesophageal echocardiography: EACVI update 2014. *European Heart Journal: Cardiovascular Imaging*. 2014;15:353-65.
 23. Meredith EL, Masani ND. Echocardiography in the emergency assessment of acute aortic syndromes. *European Journal of Echocardiography*. 2009;10:i31-i39
 24. Côté G, Denault A. Transesophageal echocardiography-related complications. *Canadian Journal of Anesthesia*. 2008;55:622-47

25. Evangelista A, Rabasa JM, Mosquera VX, Barros A, Fernández-Tarrio R, Calvo-Iglesias F, et al. Diagnosis, management and mortality in acute aortic syndrome: results of the Spanish Registry of Acute Aortic Syndrome (RESA-II). *Eur Heart J Acute Cardiovasc Care*. 2018;7:602-8.
26. Evangelista A, Garcia del Castillo H, González-Alujas MT, Domínguez Oronoz R, Salas A, Soler-Soler J. Diagnosis of ascending aorta dissection by transesophageal echocardiography. Utility of M-mode in the detection of artifacts. *Journal of the American College of Cardiology* 1996;27:102-7.
27. MacKnight BM, Maldonado Y, Augoustides JG, Cardenas RA, Patel PA, Ghadimi K, et al. Aortic Syndromes: focus on transesophageal echocardiography and type A aortic dissection for the perioperative echocardiographer. *J Cardiothorac Vasc Anesth*. 2016;30:1129-41.
28. Nienaber CA¹, Spielmann RP, von Kodolitsch Y, Siglow V, Piepho A, Jaup T, et al. Diagnosis of Thoracic Aortic Dissection Magnetic Resonance Imaging Versus Transesophageal Echocardiography. *Circulation*. 1992;85:434-47.
29. Shiga T¹, Wajima Z, Apfel CC, Inoue T, Ohe Y. Diagnostic accuracy of transesophageal echocardiography, helical computed tomography, and magnetic resonance imaging for suspected thoracic aortic dissection: systematic review and meta-analysis. *Arch Intern Med*. 2000;166:1350-6.
30. Sommer T, Fehske W, Holzknecht N, Smekal AV, Keller E, Lutterbey G, et al. Aortic dissection: a comparative study of diagnosis with spiral CT, multiplanar transesophageal echocardiography, and MR imaging. *Radiology*. 1996;199:347-52.

31. Pepi M, Campodonico J, Galli C, Tamborini G, Barbier P, Doria E, et al. Rapid Diagnosis and Management of Thoracic Aortic Dissection and Intramural Haematoma: a Prospective Study of Advantages of Multiplane vs. Biplane Transoesophageal Echocardiography. *Eur J Echocardiogr.* 2000;1:72-9.
32. Penco M, Paparoni S, Dagianti A, Fusilli C, Vitarelli A, De Remigis F, et al. Usefulness of transesophageal echocardiography in the assessment of aortic dissection. *Am J Cardiol.* 2000;86:53G-56G.
33. Sasaki S, Watanabe H, Shibayama K, Mahara K, Tabata M, Fukui T, et al. Three-dimensional transesophageal echocardiographic evaluation of coronary involvement in patients with acute type A aortic dissection. *J Am Soc Echocardiogr.* 2013;26:837-45.
34. Bansal RC, Chandrasekaran K, Ayala K, Smith DC. Frequency and Explanation of False Negative Diagnosis of Aortic Dissection by Aortography and Transesophageal Echocardiography. *J Am Coll Cardiol.* 1995;25:1393-401.
35. Erbel R, Engberding R, Daniel W, Roelandt J, Visser C, Rennollet HR. Echocardiography in diagnosis of aortic dissection. *Lancet.* 1989;1:457-61.
36. Monaco F, De Luca M, Sardo S, Cornero G, Mattioli C, Zangrillo A. Transesophageal echocardiography in the management of patients undergoing procedures for Type B aortic dissection. *Aortic dissection - Patients true stories and the innovations that saved their lives.* Editors: Edi-Ermes 2016;40:425-39
37. Erbel R, Oelert H, Meyer J, Puth M, Mohr-Katoly S, Hausmann D, et al. Effect of Medical and Surgical Therapy on Aortic Dissection Evaluated by

- Transesophageal Echocardiography Implications for Prognosis and Therapy. *Circulation*. 1993;87:1604-15.
38. Atar S, Nagai T, Birnbaum Y, Harold JG, Luo H, Naqvi TZ, et al. Transesophageal Echocardiographic Doppler Findings in Patients With Penetrating Aortic Ulcers. *Am J Cardiol*. 1999;83:133-5
 39. Willens HJ, Kessler KM. Transesophageal echocardiography in the diagnosis of diseases of the thoracic aorta: part II-atherosclerotic and traumatic diseases of the aorta. *Chest*. 2000;117:233-43.
 40. Joint Working Group. Guidelines for diagnosis and treatment of aortic aneurysm and aortic dissection (JCS 2011): digest version. *Circ J*. 2013;77:789-828.
 41. Vilacosta I, San Román JA, Aragoncillo P, Ferreirós J, Mendez R, Graupner C, et al. Penetrating atherosclerotic aortic ulcer: documentation by transesophageal echocardiography. *J Am Coll Cardiol*. 1998;32:83-9.
 42. Shimizu H, Yoshino H, Udagawa H, Watanuki A, Yano K, Ide H, et al. Prognosis of aortic intramural hemorrhage compared with classic aortic dissection. *Am J Cardiol*. 2000;85:792-5.
 43. Sundt TM. Intramural hematoma and penetrating atherosclerotic ulcer of the aorta. *Ann Thorac Surg*. 2007;83:S835-41;discussion S846-50.
 44. Movsowitz HD, Lampert C, Jacobs LE, Kotler MN. Penetrating atherosclerotic aortic ulcers. *Am Heart J*. 1994;128:1210-7.

45. Lebreton G, Litzler PY, Bessou JP, Doguet F. Acute aortic syndrome: a 'last glance' before incision. *Interact Cardiovasc Thorac Surg*. 2010;11:357-9.
46. Ledbetter S, Stuk JL, Kaufman JA. Helical (spiral) CT in the evaluation of emergent thoracic aortic syndromes. Traumatic aortic rupture, aortic aneurysm, aortic dissection, intramural hematoma, and penetrating atherosclerotic ulcer. *Radiol Clin North Am* 1999;37:575-89.
47. Harris KM, Braverman AC, Gutierrez FR, Barzilai B, Dávila-Román VG. Transesophageal echocardiographic and clinical features of aortic intramural hematoma. *J Thorac Cardiovasc Surg*. 1997;114:619-26.
48. Flachskampf FA. Assessment of aortic dissection and hematoma. *Semin Cardiothorac Vasc Anesth*. 2006;10:83-8.
49. Song JM, Kang DH, Song JK, Kim HS, Lee CW, Hong MK, et al. Clinical significance of echo-free space detected by transesophageal echocardiography in patients with type B aortic intramural hematoma. *Am J Cardiol*. 2002;89:548-51.
50. Tan GJS, Khoo PLZ, Chan KMJ. A review of endovascular treatment of thoracic aorta disease. *Ann R Coll Surg Engl*. 2018;100:662-8.
51. Grigorian A, Spencer D, Donayre C, Nahmias J, Schubl S, Gabriel V, et al. National Trends of Thoracic Endovascular Aortic Repair Versus Open Repair in Blunt Thoracic Aortic Injury. *Ann Vasc Surg*. 2018;52:72-8.
52. Grabenwoger M, Alfonso F, Bachet J, Bonser R, Czerny M, Eggebrecht H, et al. Thoracic Endovascular Aortic Repair (TEVAR) for the treatment of aortic

- diseases: a position statement from the European Association for Cardio-Thoracic Surgery (EACTS) and the European Society of Cardiology (ESC), in collaboration with the European Association of Percutaneous Cardiovascular Interventions (EAPCI). *Eur J Cardiothorac Surg.* 2012;42:17-24.
53. Koschyk DH, Nienaber CA, Knap M, Hofmann T, Kodolitsch YV, Skriabina V, et al. How to guide stent-graft implantation in type B aortic dissection? Comparison of angiography, transesophageal echocardiography, and intravascular ultrasound. *Circulation.* 2005;112:I260-4.
 54. Sobczyk D. New Approaches to Aortic Diseases from Valve to Abdominal Bifurcation. *Echocardiography in Acute Aortic Syndromes (Chapter 15).* Elsevier. 2018;159-67
 55. Erbel R, Aboyans V, Boileau C, Bossone E, Bartolomeo RD, Eggebrecht H, et al. 2014 ESC Guidelines on the diagnosis and treatment of aortic diseases: Document covering acute and chronic aortic diseases of the thoracic and abdominal aorta of the adult. The Task Force for the Diagnosis and Treatment of Aortic Diseases of the European Society of Cardiology (ESC). *Eur Heart J.* 2014;35:2873-926.
 56. Moher D, Liberati A, Tetzlaff J, Altman DG, PRISMA Group. Preferred reporting items for systematic reviews and meta-analyses: the PRISMA statement. *PLoS Med.* 2009 Jul 21;6(7):e1000097
 57. The University Illinois at Chicago, What is the PICO Model? [Internet]. Available, from: <http://researchguides.uic.edu/c.php?g=252338&p=1683349> [cited 11.23.2019]

58. Schünemann H, Brożek J, Guyatt G, Oxman A. GRADE Handbook. Introduction to GRADE handbook. Handbook for grading the quality of evidence and the strength of recommendations using the GRADE approach. Updated October 2013. [Internet] Available from <https://gdt.grade.pro.org/app/handbook/handbook.html#h.dce0ghnajwsm> [cited 11.23.2019]
59. Reitsma JB, Glas AS, Rutjes AW, Scholten RJ, Bossuyt PM, Zwinderman AH. Bivariate analysis of sensitivity and specificity produces informative summary measures in diagnostic reviews. *J Clin Epidemiol*. 2005;58:982–90.
60. Swaminathan M, Lineberger CK, McCann RL, Mathew JP. The importance of intraoperative transesophageal echocardiography in endovascular repair of thoracic aortic aneurysms. *Anesth Analg*. 2003;97:1566-72.
61. Rocchi G, Lofiego C, Biagini E, Piva T, Bracchetti G, Lovato L, et al. Transesophageal echocardiography-guided algorithm for stent-graft implantation in aortic dissection. *J Vasc Surg*. 2004;40:880-5.
62. Koschyk DH, Nienaber CA, Knap M, Hofmann T, Kodolitsch YV, Skriabina V, et al. How to guide stent-graft implantation in type B aortic dissection? Comparison of angiography, transesophageal echocardiography, and intravascular ultrasound. *Circulation*. 2005;112:I260-4.
63. Agricola E, Slavich M, Rinaldi E, Bertoglio L, Civilini E, Melissano G, et al. Usefulness of contrast-enhanced transoesophageal echocardiography to guide thoracic endovascular aortic repair procedure. *Eur Heart J Cardiovasc Imaging*. 2016;17:67-75.

64. Moskowitz DM, Kahn RA, Konstadt SN, Mitty H, Hollier LH, Marin ML. Intraoperative transoesophageal echocardiography as an adjuvant to fluoroscopy during endovascular thoracic aortic repair. *Eur J Vasc Endovasc Surg.* 1999;17:22-7.
65. Rapezzi C, Rocchi G, Fattori R, Caldarera I, Ferlito M, Napoli G, et al. Usefulness of transesophageal echocardiographic monitoring to improve the outcome of stent-graft treatment of thoracic aortic aneurysms. *Am J Cardiol.* 2001;87:315-9.
66. Gonzalez-Fajardo JA, Gutierrez V, San Roman JA, Serrador A, Arreba E, Del Rio L, et al. Utility of intraoperative transesophageal echocardiography during endovascular stent-graft repair of acute thoracic aortic dissection. *Ann Vasc Surg.* 2002;16:297-303.
67. Evangelista A, Flachskampf FA, Erbel R, Antonini-Canterin F, Vlachopoulos C, Rocchi G, et al. Echocardiography in aortic diseases: EAE recommendations for clinical practice. *Eur J Echocardiogr* 2010;11:645e58.
68. Sampaio SM, Shin SH, Panneton JM, Andrews JC, Bower TC, Cherry KJ, et al. Intraoperative endoleak during EVAR: frequency, nature, and significance. *Vasc Endovascular Surg.* 2009;43:352-9.
69. Orihashi K1, Matsuura Y, Sueda T, Watari M, Okada K, Sugawara Y, et al. Echocardiography-assisted surgery in transaortic endovascular stent grafting: role of transesophageal echocardiography. *J Thorac Cardiovasc Surg.* 2000;120:672-8.

70. Imai H, Ohashi N, Yoshida T, Okamoto T, Kitamura N, Tanaka T, et al. Intraoperative Detection of Persistent Endoleak by Detecting Residual Spontaneous Echocardiographic Contrast in the Aneurysmal Sac During Thoracic Endovascular Aortic Repair. *Anesth Analg*. 2017;125:417-20.
71. Schütz W, Gauss A, Meierhenrich R, Pamler R, Görich J. Transesophageal echocardiographic guidance of thoracic aortic stent-graft implantation. *J Endovasc Ther*. 2002;9:II14-9.
72. Crimi E, Lee JT, Dake MD, van der Starre PJ. Transesophageal echocardiography guidance for stent-graft repair of a thoracic aneurysm is facilitated by the ability of partial stent deployment. *Ann Vasc Surg*. 2012;26:861.e7-9.

Tables

Table I. The general and specific indications of TEE. Specific indications are associated with interventional procedures guided using echocardiography.

General indications	Specific indications
Evaluation of cardiac and aortic structure and function when TTE will or may not be diagnostic or alter management	Intra-procedural TEE
Critically ill patients	Guidance in trans-catheter procedures

Table II. P.I.C.O. (patient; intervention; comparison; outcome) model was used to define the clinical questions and clinically relevant evidence in the literature

P	Patient, population or problem	Patients with acute or chronic thoracic pathologies
I	Intervention, prognostic factor or exposure	The intra-operative use of TEE during TEVAR
C	Comparison of intervention	The intra-operative TEE during TEVAR in comparison to standard angiography
O	Outcome you would like to measure or achieve	The sensitivity and specificity of TEE during TEVAR in comparison to standard angiography
	What type of question are you asking?	Is TEE more sensitive than standard angiography during TEVAR procedures?
		Is TEE more specific than standard angiography during TEVAR procedures?
	Type of study you want to find	Cohort observational trials; prospective and retrospective; comparing the use of TEE to standard angiography during TEVAR procedures for acute or elective thoracic aortic pathologies
TEE: transesophageal echocardiography; TEVAR: thoracic aorta endovascular repair		

Quality assessment							Summary of findings				
							No of patients	Effect			
No studies	Study design	Risk of bias	Inconsistency	Indirectness	Imprecision	Other considerations	TEE during TEVAR	Sensitivity	Specificity		
Detection of main or new entry points after the insertion of the endograft; assessed as the detection of entry points intra-operatively using TEE vs standard angiography											
2	2 observational cohort studies; 2 prospective	Not serious	Not serious	Serious	Serious	None	84	NA	NA	Low xxoo	Critical
Guidewire advancement during TEVAR procedures; assessed as the insertion of the guidewire into the true lumen, detected using TEE vs standard angiography											
4	4 observational cohort studies; 3 prospective	Serious	Not serious	Not serious	Serious	None	150	96.9%	12.9%	Low xxoo	Critical
Graft incomplete deployment during TEVAR procedures; assessed as the malformation of the endograft after deployment detected with TEE vs standard angiography											
2	2 observational cohort studies; 2 prospective	Not serious	Serious	Serious	Serious	None	84	NA	NA	Very low xooo	Important
Early endoleaks after graft deployment; assessed as the presence of flow outside the inserted endograft detected using TEE vs standard angiography											
6	6 observational cohort studies; 5 prospective	Serious	Serious	Not serious	Serious	None	168	87.7%	76%	Very low xooo	Important

Table III. Grading of the retrieved articles with regard to the quality of evidence. NA: not applicable

Outcomes	Number of participants Studies Follow-up	Quality of evidence (GRADE)	Relative effect (CI 95%)	Conclusions	Recommendations
Detection of main or new entry points	84 pts, 2 studies, ^{61,62} Intra-operative	Low xxoo	Sensitivity 83-99% Specificity 5-8%	There is a very small body of low quality of evidence that there is a high sensitivity and low specificity for TEE in the detection of entry points in comparison to standard angiography	Further evidence from high-quality studies is needed
Guidewire advancement during TEVAR procedures	150 pts, 4 studies, ^{61,62,63,65} Intra-operative	Low xxoo	Sensitivity 96.9% Specificity 12.9%	There is a very small body of low quality of evidence that there is a high sensitivity and low specificity for TEE in the detection of the guidewire advancement into the true lumen in comparison to standard angiography	Further evidence from high-quality studies is needed
Graft incomplete deployment during	84 pts, 2 studies, ^{62,63} Intra-operative	Very low xooo	Sensitivity 92-94%	There is a very small body of very low quality of evidence that	Further evidence from high-quality studies is needed

TEVAR procedures			Specificity 4-6%	there is a high sensitivity and low specificity for TEE in the detection of graft incomplete deployment during TEVAR in comparison to standard angiography	
Early endoleaks after graft deployment	168 pts, 6 studies, ^{60-63,65,66} Intra-operative	Very low xooo	Sensitivity 87.7% Specificity 76%	There is a very small body of very low quality of evidence that there is a high sensitivity and low specificity for TEE in the detection of early endoleaks in comparison to standard angiography	Further evidence from high-quality studies is needed

Table IV. Summary of evidence. Pts: participants; TEE: transesophageal echocardiography; TEVAR; thoracic aorta endovascular repair

Figures

Figure I.

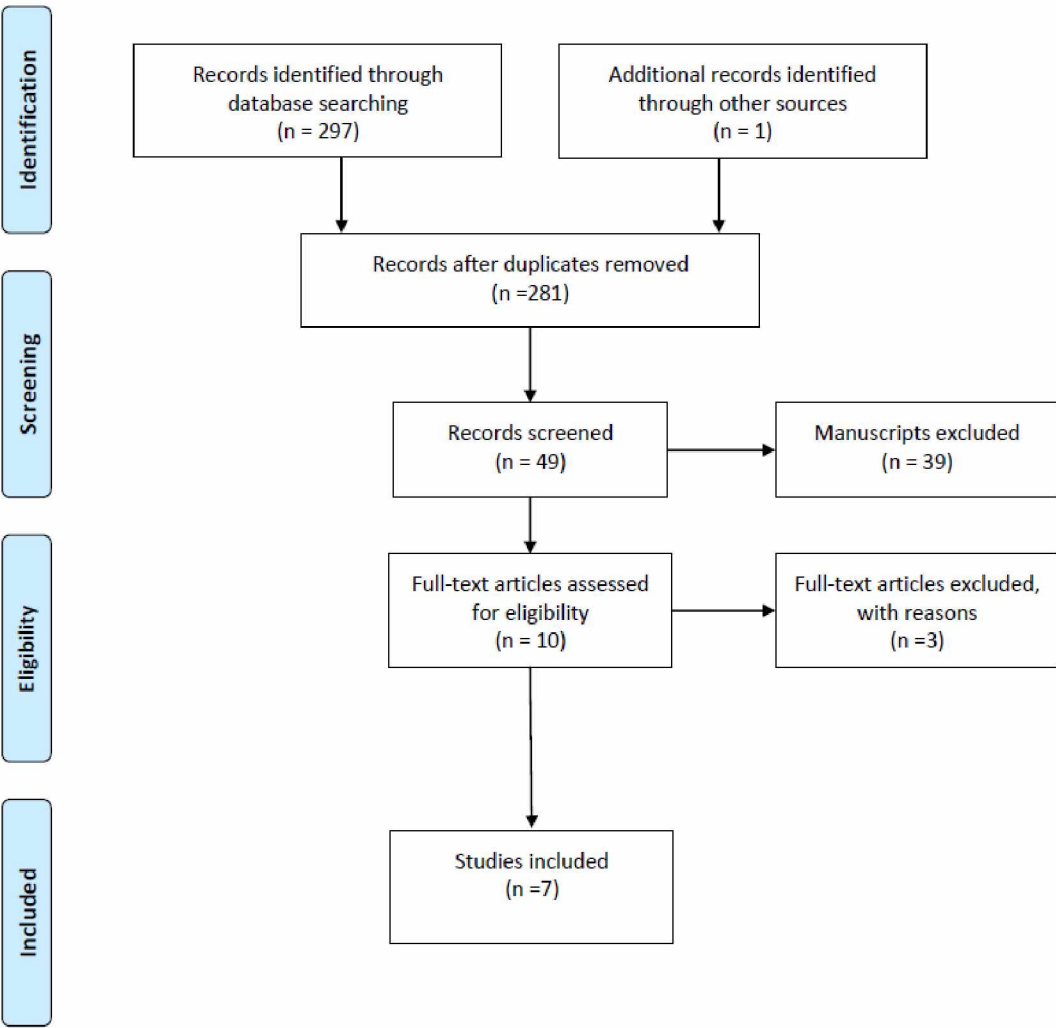


Figure II.

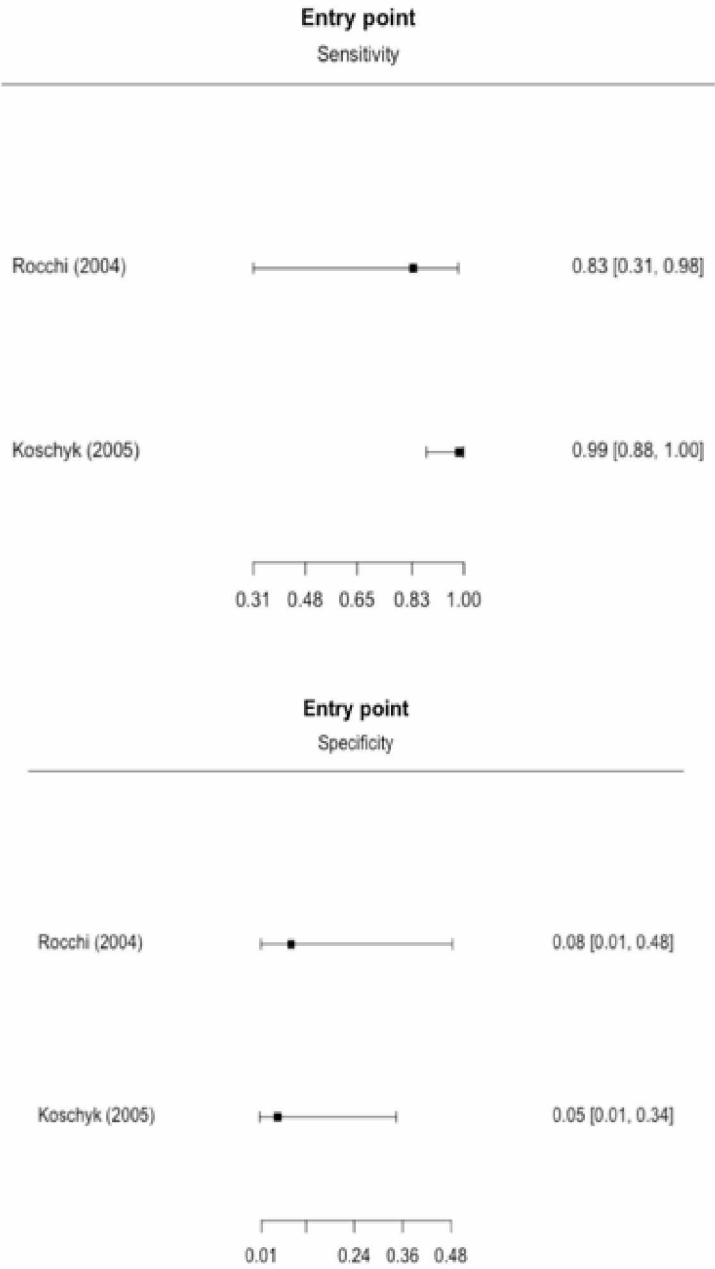


Figure III.

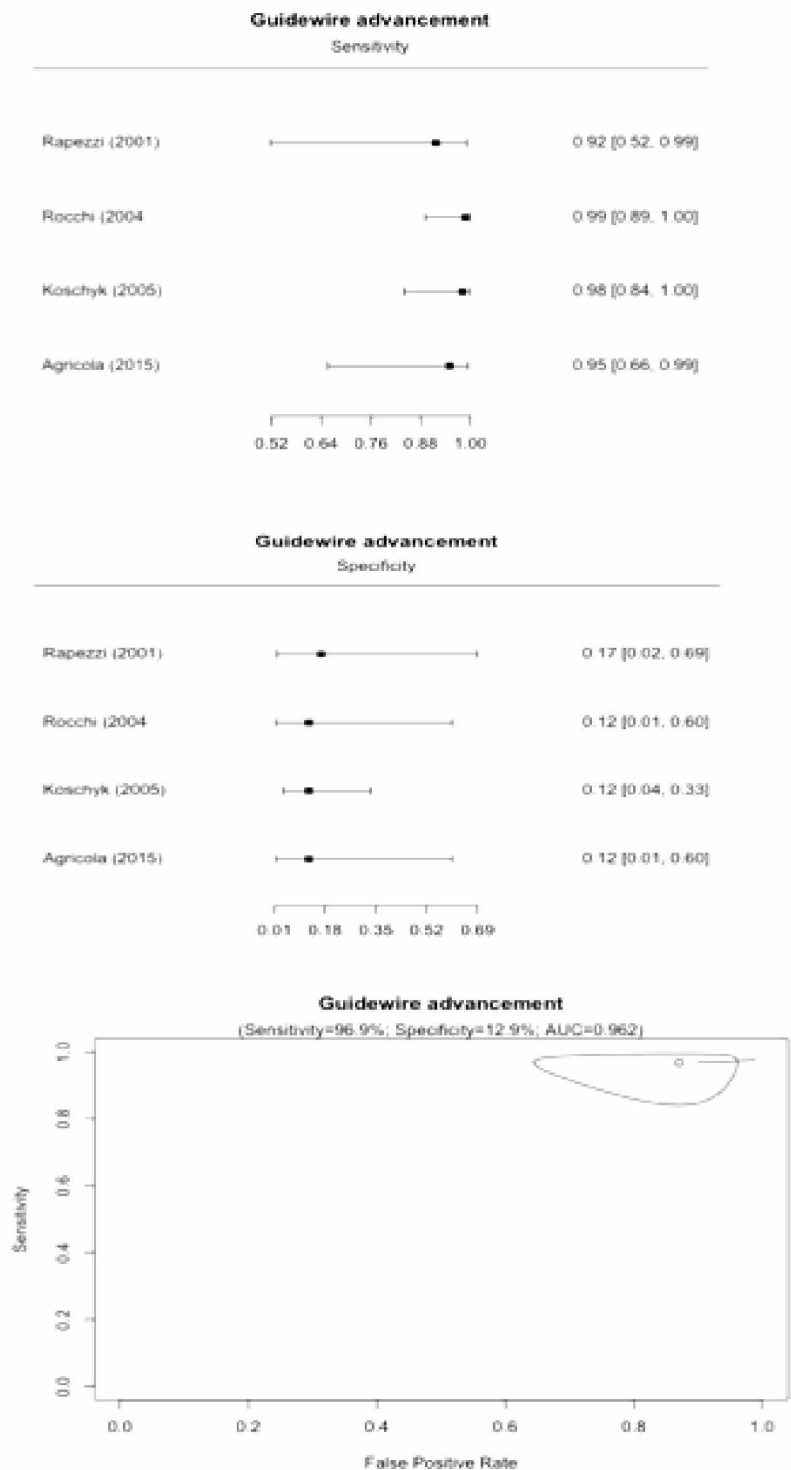


Figure IV.

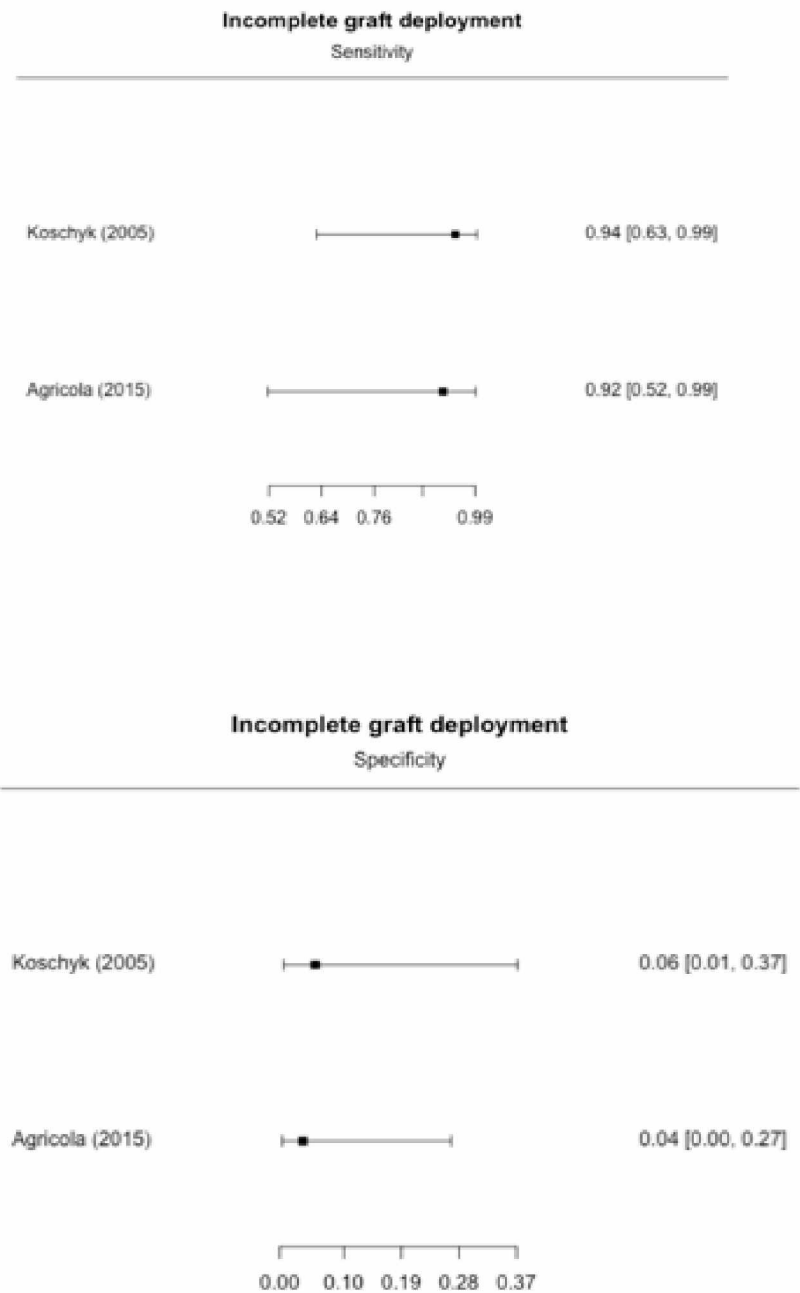


Figure V.

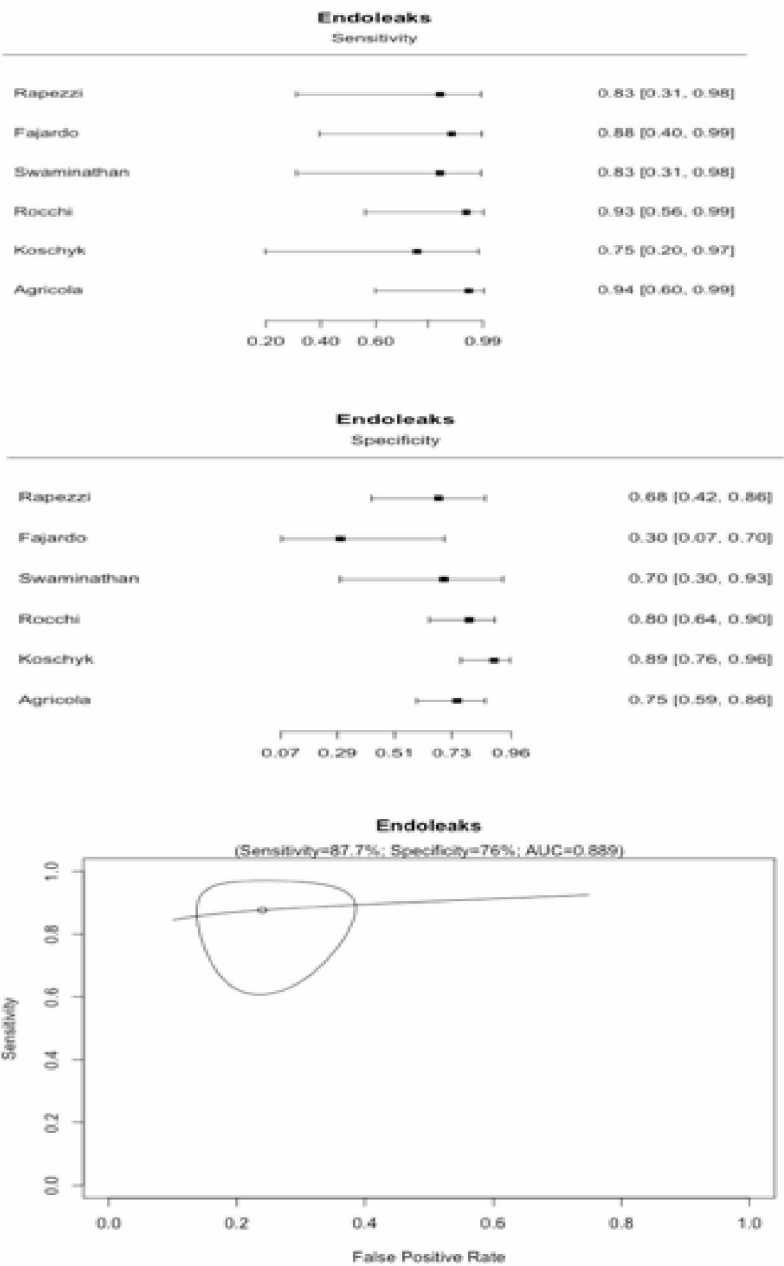


Figure legends

Figure I. The PRISMA flow chart. The final analysis included 7 articles published between 1999 and 2015, with a total of 183 patients.

Figure II. Concerning the detection of the main entry point or new entry points, 2 studies have been included in the analysis, with a TEE sensitivity and specificity estimated between 83-99% and 5-8%, respectively.

Figure III. Guidewire advancement into the true lumen has sensitivity estimated for TEE at 96.9% and a very low specificity (12.9%).

Figure IV. TEE sensitivity remains highly acceptable ranging 92-94% while specificity is low (4-6%) for the detection of incomplete graft deployment.

Figure V. The intra-operative detection of endoleaks may be achievable with TEE with a high sensitivity at 87.7% and specificity at 76%.