ΠΑΝΕΠΙΣΤΗΜΙΟ ΘΕΣΣΑΛΙΑΣ
ΣΧΟΛΗ ΕΠΙΣΤΗΜΩΝ ΥΓΕΙΑΣ
ΤΜΗΜΑ ΙΑΤΡΙΚΗΣ
ΠΡΟΓΡΑΜΜΑ ΜΕΤΑΠΤΥΧΙΑΚΩΝ ΣΠΟΥΔΩΝ
ΧΕΙΡΟΥΡΓΙΚΗ ΕΛΑΣΣΟΝΟΣ ΠΥΕΛΟΥ ΚΑΙ ΠΕΡΙΝΕΟΥ

ΔΙΠΛΩΜΑΤΙΚΗ ΕΡΓΑΣΙΑ

Genital Gender–Affirming Surgery
Χειρουργική Επαναπροσδιορισμού του Φύλου

Ακρίβου Δήμητρα
Ειδικευόμενη Ουρολογίας, Γενικό Νοσοκομείο Λάρισας

ΤΡΙΜΕΛΗΣ ΣΥΜΒΟΥΛΕΥΤΙΚΗ ΕΠΙΤΡΟΠΗ

Καρατζάς Αναστάσιος, Αναπλ. Καθηγητής Ουρολογίας ….. Επιβλέπων Καθηγητής

Μπαλογιάννης Ιωάννης, Επίκ. Καθηγητής Χειρουργικής ….. Μέλος Τριμελούς Επιτροπής

Συμεωνίδης Δημήτριος, Επίκ. Καθηγητής Χειρουργικής ….. Μέλος Τριμελούς Επιτροπής

Λάρισα, 15/10/2022

Institutional Repository - Library & Information Centre - University of Thessaly
15/10/2023 05:08:07 EEST - 167.114.118.212

Institutional Repository - Library & Information Centre - University of Thessaly
15/10/2023 05:08:07 EEST - 167.114.118.212

Table of Contents

1.	**Abstract (English & Greek)**	**3**
2.	**Introduction**	**5**
	Historic Overview of Transgender Medicine	**6**
	Diagnostic Criteria and Terminology	**7**
	Epidemiology	**9**
	Etiological hypothesis and factors	**10**
	Health burden in transgender people	**11**
3.	**Overview of Surgical Procedures**	**12**
4.	**Feminising Genital GAS**	**16**
	General Information	**16**
	Historical Overview	**16**
	Surgical Procedures	**17**
	Complications	**23**
5.	**Masculinising Genital GAS**	**25**
	General Information	**25**
	Historical Overview	**26**
	Surgical Procedures	**27**
	Complications	**31**
6.	**Conclusion**	**32**
7.	**References**	**33**
8.	**Appendix**	**40**

Institutional Repository - Library & Information Centre - University of Thessaly
15/10/2023 05:08:07 EEST - 167.114.118.212

Ευχαριστίες

Ευχαριστώ από καρδιάς τον επιβλέποντα Καθηγητή μου, κύριο Αναστάσιο Καρατζά, για την υποστήριξη και την καθοδήγηση του στην εκπόνηση της εργασίας μου, με ένα θέμα που τείνει αμήχανα να παραλείπεται αναφορών ακόμα και στην εποχή μας. Καθώς και στην υπόλοιπη τριμελή επιτροπή, τους κυρίους Μπαλογιάννη Ιωάννη και Συμεωνίδη Δημήτριο.

Οι λέξεις δεν μπορούν να περιγράψουν όσα χρωστάω στην οικογένεια μου για την υποστήριξη, όχι μόνο κατά τη διάρκεια των μεταπτυχιακών μου σπουδών, άλλα σε όλη μου τη σταδιοδρομία. Η μαμά μου, Παναγιώτα, ο μπαμπάς μου, Σταύρος, και η αδερφή μου, Ναυσικά, είναι πάντα εκεί για να πιστεύουν σε εμένα ακόμα και όταν δεν πιστεύω εγώ.

Τέλος, ιδιαίτερη ευχαριστία οφείλω στη φίλη μου Χαρά, που είναι το δεύτερο σπίτι μου.

Institutional Repository - Library & Information Centre - University of Thessaly
15/10/2023 05:08:07 EEST - 167.114.118.212

1. Abstract

Gender Dysphoria (GD) is a medical entity that needs a multidisciplinary treatment approach. Hormonal therapy is the first step of treatment and, in most cases, Gender affirming surgery (GAS) is undertaken to minimize the discomfort of GD. The term GAS includes both genital and non-genital procedures. Genital GAS is a demanding field of reconstruction surgery, requiring the involvement of multiple surgical specialties, such as urologists, plastic and general surgeons and gynecologists. As far as techniques are concerned, knowledge has been gathered mostly by treatment of amputating oncological genital procedures and genital trauma cases. For Male-To-Female individuals genital GAS options include bilateral orchiectomy and vaginoplasty with or without the creation of a vaginal canal. For Female-To-Male cases, surgical technique is far more complicated, with multiple procedures required in the majority of individuals, which include metoidioplasty, phalloplasty, glansplasty, scrotoplasty and the installation of penile and/or testicular prosthesis. In both categories, surgery comes with high rates of complications and requires strict follow-up of the patients.

Institutional Repository - Library & Information Centre - University of Thessaly
15/10/2023 05:08:07 EEST - 167.114.118.212

Περίληψη

Η Δυσφορία Φύλου είναι μια νοσολογική οντότητα που χρήζει διεπιστημονικής προσέγγισης. Η ορμονοθεραπεία αποτελεί το πρώτο βήμα για τη θεραπεία και, στις περισσότερες περιπτώσεις ακολουθεί η Χειρουργική Επαναπροσδιορισμού του Φύλου (ΧΕΦ) για την ελαχιστοποίηση της Δυσφορίας. Ο όρος ΧΕΦ περιλαμβάνει τόσο επεμβάσεις των γεννητικών οργάνων, όσο και άλλες. Οι ΧΕΦ των γεννητικών οργάνων είναι ένα πολύ απαιτητικό κομμάτι της επανορθωτικής χειρουργικής που απαιτεί τη συμβολή πολλών χειρουργικών ειδικοτήτων, όπως Ουρολόγους, Πλαστικούς, Γενικούς Χειρουργούς και Γυναικολόγους. Όσον αφορά τις τεχνικές, η γνώση γύρω από αυτές βασίστηκε κυρίως στην αντιμετώπιση ασθενών με ακρωτηριαστικά ογκολογικά χειρουργεία και τραύμα των γεννητικών οργάνων. Σε Άρρεν-Προς-Θήλυ άτομα οι επιλογές ΧΕΦ περιλαμβάνουν την αμφοτερόπλευρη ορχεκτομή και την κολποπλαστική, με ή χωρίς τη δημιουργία κολπικού καναλιού. Σε περιπτώσεις Θήλυ-Προς-Άρρεν, η χειρουργική τεχνική είναι ακόμα πιο περίπλοκη, με την ανάγκη πολλαπλών χειρουργικών επεμβάσεων στους περισσότερους ασθενείς, και περιλαμβάνει την μετα-αιδοιοπλαστική, την φαλλοπλαστική, την προσθήκη πεΐκών ή/και οσχεϊκών προθεμάτων και άλλα. Και στις δύο κατηγορίες ατόμων, οι χειρουργικές επεμβάσεις συνοδεύονται από υψηλά ποσοστά επιπλοκών και απαιτούν αυστηρή παρακολούθηση των ασθενών μετεγχειρητικά

Institutional Repository - Library & Information Centre - University of Thessaly
15/10/2023 05:08:07 EEST - 167.114.118.212

2. Introduction

Genital Gender-Affirming Surgery (Genital GAS) is the final and, most of the times, most integrating management step of Gender Dysphoria (GD). Gender dysphoria/incongruence is described as the discomfort, or even distress, that is induced by the discrepancy between one's gender identity and assigned (at birth) sex (1, 2). Treatment of GD, and GGAS specifically, is a complicated medical practice and thus requires a multidisciplinary team of multiple health professionals, such as psychologist, psychiatrists, endocrinologists, and plastic, urology, general and gynecology surgeons (3). The leading group of professionals in managing GD is World Professional Association for Transgender Health (WPATH) (4). For many years, GD has been considered a psychopathology, but nowadays progressively more people are being accepted for the identity characteristics they identify with, and transgender medicine is starting to evolve (5).

Gender Non-conformity (GN) is a different term than GD, which describes the non-conforming of an individual with the social and behavioral stereotypes, as well as the primary and secondary characteristics, of their assigned-at-birth sex. In many societies, GN may create symptoms of minority stress, which should be clarified that are not interwoven with being transgender and/or gender non-conforming (4). Not all GN individuals experience GD in their lives (4).

As mentioned above, GD is a condition which is mostly affecting people with GN, who meet the criteria of clinically significant distress and thus the diagnosis of GD is set as that is defined by the Diagnostic Statistical Manual of Mental Disorders (DSM) (American Psychiatric Association) and the International Classification of Diseases (ICD) (World Health Organization) (4). GD may be classified as a mental disorder but should not be stigmatized, as was expressed by WPATH Board of Directors in the 2010 statement: "the expression of gender characteristics, including identities, that are not stereotypically associated with one's assigned sex at birth is a common and

Institutional Repository - Library & Information Centre - University of Thessaly
15/10/2023 05:08:07 EEST - 167.114.118.212

culturally diverse human phenomenon [that] should not be judged as inherently pathological or negative." (4).

Historic Overview of Transgender Medicine

Transsexualism has always been a controversial topic in modern medicine, first documented in 1886 by German psychiatrist Richard von Krafft-Ebing, in the widely discussed *Psychopathia Sexualis* (6). Krafft-Ebing wrote this book as part of a quite controversial project about sexology and, more specifically, sexuality, which included perversions (sexual fantasies, desires, and acts) of patients, hoping to show guidance to people in the medical and legal profession (6). Notably, it did not include the word "transsexual" in it, as it had not yet been established as a term (6). In the late 19th century, it was Magnus Hirschfield who co-founded the Scientific-Humanitarian Committee in Germany, which advocated rights of sexual minorities (7). He was a sexologist whose work continued and in 1910 he published his book *Transvestites*, which first referred to the transgender population as transvestite (8). A colleague of his, Eugen Steinach, who was an endocrinologist, studied in the 1910s the morphology of sex hormones (8). In 1919, Hirschfield founded the Institute of Sexual Science, where most experiments regarding GGAS took place (9). In 1953 an american World War II veteran, named Christine Jorgensen, underwent the first successful GAS in Denmark and thus begun the attention around the topic of GAS in the US (9, 10).

For the next years, few procedures took place, due to two reasons. Firstly, it was an expensive procedure, which required the individual to spend a significant amount of money for it (11). Secondly, it was the doctors denying fulfilling patients requests, both due to lack of experience as well as acceptance (10, 11). At the time, there was a significant superiority in the amount of Male-To-Female (MTF) procedures in comparison to Female-To-Male (FTM) ones, which was based on the technical difficulties of the latter (10). In addition to that, it was believed that individuals requesting FTM procedures were fewer

Institutional Repository - Library & Information Centre - University of Thessaly
15/10/2023 05:08:07 EEST - 167.114.118.212

that those requesting MTF, so outstanding works, such as Harry Benjamin's *The Transsexual Phenomenon*, focused primarily in MTF population (12).

As the foundation of Transgender Medicine was set, more Centers were founded to facilitate the requests of GAS (10). Notably, John Hopkins University received about 2000 requests for GAS in its first 3 years of operating the Gender Identity Clinic and it is estimated that in the US around 1000 procedures took place until the end of the 1970s (10).

Ever since that era, surgical techniques of GAS have undergone a great progress mostly through implementing outcomes and adopting techniques from reconstructive surgery done for other reasons, such as traumatic amputations or amputating oncologic procedures (7). This progress in both MTF and FTM surgery will be presented in each of the topic's section below.

Diagnostic Criteria and Terminology

GD is considered a psychiatric diagnosis, which, as mentioned above, is set when some diagnostic criteria are met. The criteria are listed in the DMS, fifth edition, as displayed below (13):

GD is "A marked incongruence between one's experienced/expressed gender and natal gender of at least 6 months in duration, as manifested by at least two of the following:

A. A marked incongruence between one's experienced/expressed gender and primary and/or secondary sex characteristics (or in young adolescents, the anticipated secondary sex characteristics)

B. A strong desire to be rid of one's primary and/or secondary sex characteristics because of a marked incongruence with one's experienced/expressed gender (or in young adolescents, a desire to prevent the development of the anticipated secondary sex characteristics)

Institutional Repository - Library & Information Centre - University of Thessaly
15/10/2023 05:08:07 EEST - 167.114.118.212

C. A strong desire for the primary and/or secondary sex characteristics of the other gender

D. A strong desire to be of the other gender (or some alternative gender different from one's designated gender)

E. A strong desire to be treated as the other gender (or some alternative gender different from one's designated gender)

F. A strong conviction that one has the typical feelings and reactions of the other gender (or some alternative gender different from one's designated gender)

The condition is associated with clinically significant distress or impairment in social, occupational, or other important areas of functioning. Specify if:

A. The condition exists with a disorder of sex development.

B. The condition is post-transitional, in that the individual has transitioned to full-time living in the desired gender (with or without legalization of gender change) and has undergone (or is preparing to have) at least one sex-related medical procedure or treatment regimen—namely, regular sex hormone treatment or gender reassignment surgery confirming the desired gender (e.g., penectomy, vaginoplasty in natal males; mastectomy or phalloplasty in natal females)."

Patient care in GD, in parallel with social understanding of GD, is a continuously studied and a gradually developing field, which has, understandably, undergone a lot of changes in terms of both social and medical terminology throughout the years (5,7, 14). For the purpose of this literature review, we have collected all useful and historically significant terms, which can be reviewed in Table 1 (4, 5, 13, 15, 16).

Institutional Repository - Library & Information Centre - University of Thessaly
15/10/2023 05:08:07 EEST - 167.114.118.212

Epidemiology

Considering the social taboo around GD and transsexualism, one can speculate that the epidemiology of those has not been thoroughly studied (17). Furthermore, when studied, it is believed that numbers are underestimated (5). Prevalence and incidence have been recorded in a small number of studies throughout the years in Europe (18–24), and some studies in Asia (Singapore) (25) and USA (26, 27). The results in these studies contradict, which is expected since there is a variance in the definition and criteria of recording a person as transgender (5). As an example, the 1971 Swedish study reports an incidence of 0,15 new cases in 100.000 people per year (18). On the contrary, a more recent study in Sweden, regarding GAS, has reported incidence of 0,73 per 100.000 (MTF) and 0,42 per 100.000 (FTM) in 2010 (28), fairly increased since 1971. In addition to the 2014 analysis study from Sweden, other studies support the finding that transgender individuals are increasing through the years (29–31), with findings from a study in USA supporting that 1 in 200 people are identifying as transgender (32). As far as the age differences are concerned, a study in the US estimates a prevalence of 0,66% of individuals between 18-24 years old identifying as transgender, in contrast to 0,58% in ages between 25-64 (27).

Epidemiological statistics differ slightly when studying children and adolescent population (33). Prevalence varies in studies from 0,6% to 1,7% depending on the selection criteria and study cohort (30). Trends seem to follow the adult pattern, with Zucker et al reporting an increase in the number of both children and adolescents referred to his team from 1976 to 2007 (34). Chart 1 displays their findings (34). Although the team is specializing in children and adolescent gender medicine, they could not point a clear reason behind these findings. It could not be figured if there is indeed an increase of incidence or just an increase of individuals coming out and, also, seeking help from health professionals (34).

Institutional Repository - Library & Information Centre - University of Thessaly
15/10/2023 05:08:07 EEST - 167.114.118.212

Etiological hypothesis and factors

Etiopathology behind GD and transgenderism is still unknown (35). However, through the course of time, several scientists have hypothesized and studied the mechanisms and factors contributing to it (35). These theories could be categorized in five groups: genetic, perinatal, hormonal, anatomic and environmental.

Genetic factors have been studied as a predisposition for GD. In a general perspective, familial predisposition was studied in 2000 by Green and by Gomez-Gil et al (36, 37). Their results suggested a connection between being transgender and having a transgender sibling (36, 37). Then, a more recent study was conducted, which supported these findings, this time studying monozygotic twins (38). Further investigations on genetic factors took place to assess specific genes involving hormonal pathways, which concluded a significant correlation between GD and polymorphisms in estrogen receptor beta, androgen receptor, aromatase and CYP17 genes (39–41).

Perinatal hormonal changes appear to be an important factor altering hormonal levels in the newborn. The characteristic of the second-to-fourth finger ratio (2D:4D) has been thoroughly studied and it has been well established that it is smaller in males than in females and that it is hormone-defined prenatally (42–45). 2D:4D was found to be similar between transgender women and birth-assigned females (36), although more recent studies do not support this finding (46). In 1999, Dessens et al studied the psychosexual development in children, who were under the effect of maternal use of phenobarbital and diphenylhydantoin (47). Their studied pointed out that phenobarbital altered postnatal levels of testosterone (47).

Anatomical/structural variables in brains between controls and transgender individuals were first studied postmortem in mid-1990s (48). The results were supporting differences in the hypothalamus and the number of somatostatin neurons (48–50). Later on, due to the broader use of neuroimaging, it became

Institutional Repository - Library & Information Centre - University of Thessaly
15/10/2023 05:08:07 EEST - 167.114.118.212

easier to study such concepts with larger study populations. Cortex thickness, white matter microstructure, hemisphere dominance and brain size were the factors under investigation with varying results (51–56). Notably, the most recent review of the literature proposes a new concept: The Brain Gender (56).

Lastly, environmental factors, such as socially induced gender roles resulting in GD development, were proposed in the earliest era of GD. Then was a time when there was a more philosophical approach of GD and, thus, this hypothesis was soon debunked (57).

Health burden in transgender people

As modern medicine shifts to relying more on prevention than treatment of diseases, more research efforts are made to find predisposition factors of diseases. The findings regarding transgenderism are unfortunately disappointing, with transgender people demonstrating high prevalence/incidence of major cardiovascular events, mental health disorders and sexually transmitted infections (58–65). Poteat et al established the role of gender minority stress in elevating cardiovascular disease risk (66). In particular, in their study they found that transgender women have higher risk of venous thromboembolism (VTE) than cisgender women, as well as higher rates of discrimination and psychological distress (63, 66). Higher rates of stroke and myocardial infraction have been found in transgender and non-conforming individuals in comparison to cisgender ones (62). There was also found that despite that morbidity was higher in the non-cisgender group, there was greater chance of delaying a doctor visit in that group due to cost (63).

As far as young individuals and adolescents are concerned, there should be more studies addressing the risks and health conditions of being a transgender/non-conforming person, and there should be greater measures taken in order to minimize this population group's health burden (65, 66).

Institutional Repository - Library & Information Centre - University of Thessaly
15/10/2023 05:08:07 EEST - 167.114.118.212

3. Overview of Surgical Procedures

As mentioned before, GD is a diagnosis that is confirmed through criteria according to the DSM. The first step to treat GD is the initiation of hormone therapy (HT) (4). When GD diagnosis has been confirmed, HT can be initiated, provided the individual has been informed about the social risks and side effects of HT (67) and provided the criteria below are met (4):

1) Persistent, well-documented gender dysphoria
2) Capacity to make a fully informed decision and to consent for treatment
3) Age of majority in a given country
4) If significant medical or mental health concerns are present, they must be reasonably well-controlled

For some patients, hormone therapy is enough to comfort GD symptoms, whereas others need further treatment with surgical interventions. There is a wide variety of surgical procedures for the treatment of GD. They are categorized in three main groups: breast surgery, genital surgery and non-breast, non-genital interventions (4).

Male-To-Female Surgical Interventions

According to WPATH guidelines, MTF surgical interventions include the following (4):

1) Breast surgery: augmentation mammoplasty (implants/lipofilling)
2) Genital surgery: penectomy, orchiectomy, vaginoplasty, clitoroplasty, vulvoplasty
3) Non-breast, non-genital interventions: facial feminisation surgery, liposuction, lipofilling, vocal cord surgery, thyroid cartilage reduction,

Institutional Repository - Library & Information Centre - University of Thessaly
15/10/2023 05:08:07 EEST - 167.114.118.212

gluteal augmentation (implants/lipofilling), hair reconstruction and various aesthetic procedures.

Female-To-Male Surgical Interventions

According to WPATH guidelines, FTM surgical interventions include the following (4):

1) Breast surgery: subcutaneous mastectomy

2) Genital surgery: hysterectomy/salpingo-oophorectomy, reconstruction of the fixed part of the urethra, which can be combined with a metoidioplasty or with a phalloplasty (employing a pedicled or free vascularized flap), vaginectomy, scrotoplasty and implantation of erection and/or testicular prostheses

3) Non-breast, non-genital surgical interventions: voice surgery (rare), liposuction, lipofilling, pectoral implants and various facial masculinising aesthetic procedures.

All procedures are briefly summarised in Table 2.

Meeting GAS Criteria

GAS is the final and most definite treatment of GD and should be opted when patient fulfills specific criteria, with extreme satisfaction rates for FTM and MTF individuals of 97% and 87%, accordingly (68). However, not all patients with GD desire to undergo GAS or breast surgery and not all patients qualify for those procedures (4). An individual with GD should be evaluated by a mental health professional. After confirming the diagnosis of GD, there are criteria that should be met for a patient to be able to undergo GAS (4). The criteria for GAS, according to WPATH guidelines (4), are:

Criteria for hysterectomy and salpingo-oophorectomy in FtM patients and for orchiectomy in MtF patients:

Institutional Repository - Library & Information Centre - University of Thessaly
15/10/2023 05:08:07 EEST - 167.114.118.212

1) Persistent, well-documented gender dysphoria
2) Capacity to make a fully informed decision and to consent for treatment
3) Age of majority in a given country
4) If significant medical or mental health concerns are present, they must be well controlled
5) 12 continuous months of hormone therapy as appropriate to the patient's gender goals (unless hormones are not clinically indicated for the individual)
6) Although not an explicit criterion, it is recom- mended that these patients also have regular visits with a mental health or other medical professional.

Criteria for metoidioplasty or phalloplasty in FtM patients and for vaginoplasty in MtF patients:

1) Persistent, well-documented gender dysphoria
2) Capacity to make a fully informed decision and to consent for treatment
3) Age of majority in a given country
4) If significant medical or mental health concerns are present, they must be well controlled
5) 12 continuous months of hormone therapy as appropriate to the patient's gender goals (unless hormones are not clinically indicated for the individual)
6) 12 continuous months of living in a gender role that is congruent with their gender identity
7) Although not an explicit criterion, it is recommended that these patients also have regular visits with a mental health or other medical professional.

For all procedures mentioned above, patient should be thoroughly informed about the pros and cons of each procedure, the realistic expectations of outcome as well as the risks and complications that come with each surgical intervention (4).

Institutional Repository - Library & Information Centre - University of Thessaly
15/10/2023 05:08:07 EEST - 167.114.118.212

Benefits of GAS

Literature is poor as regards GAS satisfaction rates (17). However, published studies have shown that GAS improves patients' QOL, psychologic function and mood as well as sexual satisfaction and body image (69–73). Satisfactions rates are raging from 87% to 97% and remain high despite the high rates of complications of the procedures (68, 74, 75).

Institutional Repository - Library & Information Centre - University of Thessaly
15/10/2023 05:08:07 EEST - 167.114.118.212

4. Feminising Genital GAS

General Information

Feminising procedures include multiple surgical procedures as mentioned in the previous chapter. The order of completing the procedure is not defined by the WPATH guidelines (4). Facial feminisation includes forehead contouring, hairline advancement, rhinoplasty, gonial angle shave, thyroid cartilage shave, reduction genioplasty, lip reduction and soft-tissue fillers. Feminising breast augmentation is also part of the transition (76, 77). However, these procedures are not in the scope of this review.

Genital gender affirming surgical procedures include vaginoplasty (several techniques), orchiectomy, penectomy, urethroplasty and labiaplasty (76, 77). All procedures serve the purpose of treating patients' GD with eliminating the masculine genital characteristics and creating the desired feminine genital anatomy, and terminating the source of testosterone (with orchiectomy) (5). These goals need to be achieved with the minimum possible scarring from the donor site (site where grafts are taken from, when there is skin grafts) and with minimum overall intervention (ex. intestinal grafts are more invasive) (78). Beek et al described the "ideal" dimensions of neovagina as minimum 10cm in depth and 3cm in width (78).

Historical Overview

Vaginoplasty was firstly documented in the 19th century and was performed in cisgender women to treat congenital defects, trauma or defects due to extensive oncological surgeries (10). The first GAS vaginoplasty took place in 1931 at the Institute for Sexual Science by Hirschfield (79, 80). Through the course of time, several techniques have been described with full-thickness skin grafts, split grafts, intestinal grafts, and penile inversion (10, 81-83). Notably, in 1993, plastic surgeon Eldh first performed vaginoplasty with penile and scrotal flaps, with preservation of blood supply and innervation and clitoroplasty with glans

Institutional Repository - Library & Information Centre - University of Thessaly
15/10/2023 05:08:07 EEST - 167.114.118.212

flap in 20 MTF patients (84). Nearly all patients documented to have maintained an erogenous aesthesis (84). As of today, the gold standard in MTF genital GAS is penile inversion vaginoplasty (85).

Surgical Procedures

A. Orchiectomy

Bilateral orchiectomy/gonadectomy is a basic and only procedure to eliminate testosterone production in MTF individuals. It can be performed as a standalone procedure, when a patient does not wish/or do not qualify to undergo vaginoplasty, or it can precede vaginoplasty. Either way gonadectomy comes with multiple benefits for the patient. Following orchiectomy testosterone levels are undetectable, thus androgen-blocking agents can be discontinued and estrogen levels are maintained ideally in female range, thus estrogen dosage can be lowered (5, 86). In addition to these benefits, orchiectomy appears to be the only option in individuals who are not eligible, according to WPATH criteria, to undergo vaginoplasty (86). In a recent study, documenting patients who underwent orchiectomy, 37% of patients could not undergo vaginoplasty due to smoking, elevated BMI or health (incl. mental) problems (86). Thirty percent of all patients opted for gonadectomy as a standalone procedure in order to stop anti-testosterone agents and because it was enough of a procedure to treat their GD (86). Furthermore, orchiectomy results in less volume in the pudendal area, which makes penis less visible through pants and tucking easier and less painful for the individual (5).

As regards fertility after gonadectomy, patients should be informed about the possibility of cryopreservation of sperm before the initiation of hormonal therapy (4, 87).

The procedure is performed transscrotally through a vertical midline incision and will be described in more detail as part of Vaginoplasty section.

Institutional Repository - Library & Information Centre - University of Thessaly
15/10/2023 05:08:07 EEST - 167.114.118.212

B. Vaginoplasty

The options for an MTF individual seeking genital GAS can be divided in two main categories: complete vaginoplasty without vaginal canal creation and complete vaginoplasty with vaginal canal creation (5, 88, 89). Vaginal canal can be created by:

1) Penile Inversion Vaginoplasty (PIV) alone,
2) PIV with free full-thickness scrotal skin grafts,
3) PIV with pedicled scrotal skin graft, or
4) PIV with intestinal graft

Anatomy

Before explaining in detail the surgical techniques of vaginoplasty, we are obliged to refer briefly to male anatomy in our surgical site. External genitalia include penis and testes (90). Penis consists of three high vascularized spongy bodies: two corpora cavernosa dorsally and one corpus spongiosum which circulates the distal urethra (90). The topographic anatomy, vasculature and innervation is illustrated in Figure 2. Both corpora cavernosa are surrounded by a multilayered connective tissue called tunica albuginea. These with corpus spongiosum and all penile vessels and nerves are enveloped in Buck's fascia (deep), Colle's fascia (superficial) and penile skin (90). Colle's fascia also includes the testicles (91), as illustrated in Figure 3. Both testicles are included in a layer of skin, the scrotum. Under the skin is the dartos muscle and deeper to that are three layers of fascia deriving from the abdominal wall layers. Deeper that the layer is the tunica vaginalis. Inside the scrotal cavity and on top of the anterior pole of each testis lies the epididymis, which is a tubular structure that connects to vas deferens at its distal part (5, 90). Vas deferens is surrounded by the spermatic cord, moving through the internal inguinal canal (90, 92). The anatomy mentioned above is illustrated in Figure 4.

Institutional Repository - Library & Information Centre - University of Thessaly
15/10/2023 05:08:07 EEST - 167.114.118.212

As far as the internal genitalia are concerned, prostate and seminal vesicles are located in front of the rectum, on top of the urogenital diaphragm. A notable anatomical site is the fascia separating the prostate from the rectum, which is called Denonvilliers' fascia (90, 91). Denonvilliers' fascia is illustrated in Figures 3 and 4.

PIV

The "ideal" procedure, in terms of minimal technical difficulties and complication, would be penile inversion vaginoplasty alone (5, 88, 89). Before the beginning of the surgical procedure, patient is placed in lithotomy position and reference lines are marked on the surgical field, as displayed in Figure 5 (89). The incision has a butterfly shape (93). Significant surgical "landmarks" are the midline, the inguinal/groin creases, the site of the neovagina and the perineal and scrotal skin flaps, which will form the neovulva (89). The perineal skin flap is marked starting 2cm above the anus and has a trapezoid shape starting from 3,5-4,5cm (width) base to 3,0-3,5cm width when it reaches the perineum (88). The site of the neovagina is about 2cm anterior to the posterior extend of the butterfly incision (93).

After the operating plan is marked on the skin, a urethral catheter is placed and the surgical field is prepared with the use of povidone-iodine solution, covering the area from the umbilicus to the knees (88).

Surgery is done under general anesthesia (93). Surgery starts at the midline vertical perineal incision, along the midline raphae, and is then extended to the incision marks planned preoperatively. A schematic illustration of the surgical steps is shown in Figure 6. Firstly, the harvest of the skin grafts and flaps takes place. That way the male anatomy is revealed underneath the skin and surgical preparation of the structures can start (5, 88, 89, 93).

The second step of the surgery is to dissect the neovaginal canal space. This is accomplished through development of the ischioanal fossae and of the

Institutional Repository - Library & Information Centre - University of Thessaly
15/10/2023 05:08:07 EEST - 167.114.118.212

rectovesical space. Mobilization of the urethra is performed through separation the bulbospongiosus' attachments to the perineal body. Then, the perineal membrane is separated from the perineal body and perineal muscles, which enter the perineal body horizontally, are ligated and divided (88). Afterwards, a careful and deep dissection is made at the avascular tissue plane located perirectally, anterior to Denonvilliers' fascia and posterior to the prostate and bladder (5, 88). The dissection is performed until the peritoneum, creating a deep area which will be the neovaginal canal space, as shown in Figure 7. Before progressing to the next step of the operation, the surgeons must check for any possible rectal trauma by inserting a clean gauze/sponge in the neovaginal space and then instilling 60ml of povidone-iodine solution in the rectum. If iodine solution is found on the gauze, the rectum was traumatized during the dissection (88).

The third step of the operation is bilateral orchiectomy, in the cases of individuals who have not undergone gonadectomy before undergoing vaginoplasty. Both testicles are mobilized, separated from the scrotal cavity, and spermatic cord is ligated bilaterally at the level of the external inguinal ring (88).

The next step is the degloving of the penis and preparation of the urethra. This is done by a circumferential incision about 3cm from the corona, degloving the penis from the skin while maintaining Buck's fascia intact (88, 89). The penile skin will be later used to construct the clitoral hood and libia minora. Then, the neurovascular bundle (NVB) of the penis is carefully separated from the corpora, all the way until the corona. The dorsal vein and sensory nerves to the glans penis are preserved, so that the dorsal part of glans penis can be used to create the neoclitoris. On the dorsal penile glans, a small 1cm dimension triangle is incised and preserved, which will later form the neoclitoris (88). Both corpora spongiosum are separated and amputated. Afterwards, the bulbospongiosum is resected off the urethra (*mark that remnants of the*

Institutional Repository - Library & Information Centre - University of Thessaly
15/10/2023 05:08:07 EEST - 167.114.118.212

spongiosum on the ventral side of the urethra will enlarge during sexual arousal and may narrow the neovagina during intercourse) and the urethra is transected.

Lastly, the reconstruction is ready to start. The penile flap, which was created before, is positioned on the neovaginal space and the neoclitoris is created about 1 centimeter below the pubic arch and the NVB is folded toward the perineum to maintain sensation at the area (88, 89). Labia majora are then created from the penoscrotal skin bilaterally. The neovagina is created by positioning the neovaginal tube that was created earlier. A V-shaped incision is made for the neoclitoris, which is extended vertically to accommodate the meatus. Then, the urethra and foley catheter are passed through that space. The neoclitoris is slightly altered by a square stitch at the level of adductor longus tendon which gives it a conical shape and the clitoral hood is constructed by suturing the distal penile shaft skin on the edges of the V-shaped clitoral space. The urethra is transected to be at the correct length, one that reaches the neoclitoris, and it is sutured on the posterior edge of it, as in the original female anatomy. Finally, the perineoscrotal skin flap is inset into the midline incision to make the neovaginal introitus wider, the apex of the penile skin tube is sutured, all reconstructed neovagina is positioned inside the neovaginal space and now all skin is closed. The neovagina is filled with a vaginal packing or a stent, so it is maintained in position for 5 days (88, 89).

PIV with skin grafts

Skin grafts are historically significant since they date back to the 1930s (94). However, the use of them comes with some disadvantages that have resulted in their elimination and use only when there is not adequate tissue for the creation of a sufficient vaginal canal depth (94-96). The disadvantages of skin grafts are: scarring and neovaginal stenosis (incidence rates up to 45%), scarring and discoloration of the donor site, lack of natural lubrication, requirement of preoperative hair removal (5, 94-96).

Institutional Repository - Library & Information Centre - University of Thessaly
15/10/2023 05:08:07 EEST - 167.114.118.212

In modern clinical practice, when needed, PIV is augmented with the use of full-thickness scrotal skin (5). In this case, a full-thickness 10x5cm (width x length) rectangle scrotal skin segment is removed and defatted. Afterwards, the segment is sutured to form a tube around a vaginal stent, as displayed in Figure 8, which is going to be the neovagina apex, and the tube created is sutured to the tube-shaped penile skin to further extend the depth of the neovaginal canal (5, 88, 93).

PIV with pedicled scrotal skin graft

When performing PIV with pedicled scrotal skin graft, a segment of perineal and midline scrotal skin is prepared to augment the penile tube with an end-to-end anastomosis (5).

PIV with intestinal graft

PIV with intestinal graft is a method with promising results as far as quality-of-life (QoL), function and esthetics is concerned, but remains a more invasive method of vaginoplasty since it involves intrabdominal surgery (5, 88, 93, 97). The intestinal graft is usually a rectosigmoid or ileal segment, which is used to create the neovaginal canal, and has the advantage of natural lubrication due to the intestinal mucosa (5, 88). Intestinal graft vaginoplasty is also a promising option for individuals requiring secondary vaginoplasty, as for example in cases of stenosis after primary procedure (88).

Vaginoplasty without the creation of vaginal canal

After vaginoplasty, patients are bound to commit to a strict dilation schedule to maintain the depth and width of the neovaginal canal. Thus, the option of vaginoplasty without a vaginal canal, or shallow-depth vaginoplasty, is an ideal option for patients who do not wish to commit to the dilation routine. Furthermore, not all transgender women require vaginal intercourse to reach an orgasm, so shallow-depth vaginoplasty is an option for those women too (5). As

Institutional Repository - Library & Information Centre - University of Thessaly
15/10/2023 05:08:07 EEST - 167.114.118.212

regards the technical aspect of the procedure, the same steps are followed as in PIV without the reconstruction of the neovaginal space.

C. Preoperative preparation

Individuals undergoing GAS should be approached holistically by the team of doctors and should be in good health (98). All preexisting medical conditions should be well controlled, including smoking (4, 85, 98). Diabetes mellitus is a common condition that should be well controlled (goal: hemoglobin A1c level < 7%) since it affects wound healing. Smoking cessation is ideal for at least 6 weeks before and after surgery since it also affects healing and is linked with increased risk of deep vein thrombosis (DVT) (4, 85, 99). Other measures for DVT prophylaxis are estrogen discontinuation for 2 weeks before and after surgery, as well as low-molecular-weight heparin initiation intraoperatively (99). The neovagina is reconstructed using hair-bearing epithelium (penile, scrotal, or perineal), thus preoperative hair removal of the area is strongly recommended. Finally, all patients should undergo mechanical bowel preparation because it is linked with better chances of rectal healing when there is rectal injury intraoperatively (88).

D. Complications

Vaginoplasty comes along with a wide range of complications, as does any major surgical intervention. Major complications, such as DVT and pulmonary embolism are rare (85, 97, 100, 101). Most common complications are urinary and would complications (88). Specifically, up to 40% of patients will present with a misdirected urinary stream and up to 30% with wound healing problems such as dehiscence and necrosis (mainly minor) (85, 88, 97, 100, 101). These problems are treated with surgery (ventral meatoplasty) and conservatively, respectfully (88). Other common complications are urinary incontinence, lower urinary tract symptoms (LUTS), such as urgency, frequency, and weak stream, wound infection and meatal or introital stenosis (88).

Institutional Repository - Library & Information Centre - University of Thessaly
15/10/2023 05:08:07 EEST - 167.114.118.212

As regards PIV with intestinal graft, it comes with more complications as it involves intrabdominal surgery. Ileus and peritonitis are the most common gastrointestinal complications, presenting in less that 5% of the patients undergoing PIV with intestinal grafts (88).

E. Postoperative considerations

Vaginal Dilation

As mentioned before, PIV with a vaginal canal demands lifelong commitment of vaginal dilatation to maintain adequate vaginal canal width for intercourse (5).

Kegel Exercises

Patients undergoing PIV should be encouraged to perform Kegel exercises to learn how to relax pelvic muscles (5). This way they will avoid uncontrolled pelvic floor contraction, which would otherwise result in difficulty voiding and pain with dilation.

Prostate Cancer

In MTF GCS, the prostate gland is not removed in order for potency to be maintained. Thus, transgender women and their doctors should be informed about the chance of prostate cancer (5). As of today, there are no definitive guidelines about PSA and rectal exam screening in transgender individuals.

Institutional Repository - Library & Information Centre - University of Thessaly
15/10/2023 05:08:07 EEST - 167.114.118.212

5. Masculinising Genital GAS

General Information

As in feminising cases, masculinising procedures include both genital and non-genital procedures. Facial masculisation includes lipofilling, liposuction, facial masculinisation and vocal cord surgery. The last two procedures are rarely performed. Most transgender men do not opt for facial procedures since testosterone therapy achieves the desired facial changes (102). Interestingly, a thyroid cartilage augmentation technique, using autologous rib cartilage, has been recently reported (103). Other non-genital GAS procedures include: mastectomy, chest contouring and pectoral implants (102). For most individuals, mastectomy is the only procedure they choose to undertake and is adequate to treat GD (4).

Genital gender affirming surgical procedures include hysterectomy, salpingo-oopherectomy, vaginectomy, metoidioplasty, phalloplasty, scrotoplasty, testicular prosthesis, penile prosthesis, glansplasty and auxiliary urethral lengthening in some procedures (102). The purpose of these procedures is to treat patients' GD firstly by eliminating the feminine genital characteristics and secondly by creating the desired masculine genital anatomy while achieving micturition in a standing position and adequate sexual function (5). Metoidioplasty and phalloplasty are the main procedures for FTM GAS. Metoidioplasty is the procedure through which a micropenis is created from patients clitoris glans and phalloplasty is the procedure through which a phallus is created using skin and adipose skin flaps from different parts of patient's body (5).

Procedure staging

FTM GAS requires multiple procedures to achieve an anatomic result close to cisgender male. These procedures are divided in three stages with a minimum interval of 4 months between each stage (5). In stage I, metoidioplasty with or

Institutional Repository - Library & Information Centre - University of Thessaly
15/10/2023 05:08:07 EEST - 167.114.118.212

without urethral lengthening OR phallourethroplasty is performed, depending on the needs of the patient, as explained above. Stage II includes perineal urethrostomy vaginectomy and glansplasty (illustrated in Figure 9) alone or combined with laparoscopic hysterectomy. Lastly, stage III is performed by a urologist and includes the placement of penile prosthesis (mostly inflatable) to facilitate erection and testicular prosthesis to reach optimal external genitalia aesthetic result (5).

Historical Overview

Phalloplasty, historically, was, as vaginoplasty, studied as an option for treating patients who had suffered penile injuries (7). Bogoraz Nikolaj has first described, in 1936, a total phalloplasty technique using an abdominal flap and autologous rib cartilage (104). Later on, during World War I, phalloplasty was used in soldiers who had suffered penile trauma (10). In 1946, a british physician, Laurence Michael Dillone, who was born female, underwent FTM GAS by Sir Harold Gillies. In the 1948, Gillies published the infamous “tube-within-a-tube” technique, which was gold standard procedure for about 40 years and which was done by using two tubed abdominal flaps, one reconstructed to form the urethra and the second one, surrounding the neourethra, to form the penis (10). Since then, multiple different techniques have been described using multiple different flaps (7). In 1973, Durfee and Rowland reported the first penile reconstruction in transgender man using the clitoris; a procedure that was later named metoidioplasty (105). Notably, in 2015, the first penile transplantation was successfully performed in a patient with traumatic amputation in South Africa (106). Hopefully, as occurred with phalloplasty, knowledge from penile transplantation in trauma reconstruction will lead the way for the former to be used in GAS as well. As of today, the gold standard in FTM genital GAS is metodioplasty and phalloplasty (5).

Institutional Repository - Library & Information Centre - University of Thessaly
15/10/2023 05:08:07 EEST - 167.114.118.212

Surgical Procedures

A. Metoidioplasty

Metoidioplasty is the procedure through which a neomicropenis is created using the hypertrophic clitoris of the patient. It was first reported in 1973 and, later in 1989, Laub et al named the procedure (107). Metoidioplasty's etymology comes from the Greek words "metamorphosis" which means change, "aidoio" which means female genitalia and the suffix "plasty" which means shape (107). In metoidioplasty, the hypertrophic effects of testosterone on the clitoris are used for patient's advantage and the hypertrophic clitoris is used to create a penis (5). The procedure can be combined with or without urethral lengthening. It is a procedure that has zero donor site scarring, since it does not require flaps, has the shortest hospital stay, lowest cost and lowest complication rate (102).

Anatomy

Before explaining the procedure, one should have a clear understanding of the anatomy of the clitoris. The clitoris has four parts; the erectile bodies, the glans clitoris, the neurovascular bundle (same course as male NVB) and the urethral ventral plate, as illustrated in Figure 10 (108). Under the effect of testosterone, these structures become hypertrophic and provide, thus, adequate tissue for the creation of a micropenis (<7cm length) (5).

Procedure

Usually, metoidioplasty is combined with urethral lengthening to facilitate urination while standing. At the beginning of the procedure, complete vaginal mucosa removal is performed (colpocleisis) with preservation of the anterior vaginal wall (109). After transection, the clitoris is mobilized by incision of the suspensory ligaments, maximizing the exposure of the clitoris, and ventral plate incision (H-shape incision). The NVB are located at the 1 and 11 o'clock positions and should be always carefully handled by the surgeons (109). When

Institutional Repository - Library & Information Centre - University of Thessaly
15/10/2023 05:08:07 EEST - 167.114.118.212

the clitoris is exposed maximally, it is placed into traction, but then on the ventral site of the neopenis there is a defect created, as shown in Figure 11. That defect is used to create the neourethra using fasciocutaneous skin flaps (eg. from labia minora) and buccal mucosa grafts, which are placed and then, into continuity with the clitoris (micropenis) creating the lengthened urethra, as illustrated in Figure 12 (109). In order to maintain the urethral lumen, a silicone tube of 14Fr is used. The rest of the penile reconstruction in completed by using labia minora and clitoral shafts. Metioidioplasty can be combined with a scrotoplasty with or without testicular prosthesis (5, 102, 107). When scrotoplasty is performed, the scrotum is created by suturing of the labia majora in midline (5, 102, 107, 109).

B. Phalloplasty

Phalloplasty is a procedure through which a full-size phallus is created. The use of skin and adipose flaps is mandatory, making it a more challenging procedure than metoidioplasty (5). Several techniques have been described throughout the years. Most commonly used are:

1) Radical artery forearm flap (RAFF) ± neourethra,
2) Anterior lateral thigh (ALT) pedicle or free flap ± neourethra,
3) Suprapubic (SP) skin pedicle flap, or
4) Groin (G) pedicle flap

The ideal phalloplasty has been defined by Hage and De Graaf as the one that has, in a one-stage procedure, created an aesthetic result which meets patient's expectations, provides erogenous sensation, and allows standing urination while having the minimal possible complications and donor site morbidity (110).

Radical artery forearm flap (RAFF)

RAFF is a free flap technique of phalloplasty which was firstly described in mid 1980s by Chang and Hwang (111) and is the most frequently used technique for

Institutional Repository - Library & Information Centre - University of Thessaly
15/10/2023 05:08:07 EEST - 167.114.118.212

the neophallus creation (112). With this technique the surgeon uses a skin and subcutaneous adipose free flap from the forearm, which is accompanied with blood supply from the forearm radial artery and innervation from the medial and lateral antebrachial cutaneous nerves (111, 112), as displayed in Figure 13 (112). The flap is divided in two segments; one is tubularized and is used to form the urethra and one used to form the penis, as illustrated in Figure 14 (112).

Anterior lateral thigh (ALT) pedicle or free flap

ALT was first described in 1984 by Song et al and is a technique that, in the same manner as RAFF, uses a skin and adipose flap from the anterior lateral thigh, with vasculature from the descending branch of the lateral circumflex femoral artery and innervation from the lateral femoral cutaneous nerve (113). As in RAFF, the flap is divided in two segments, one for the construction of the neourethra and one for the construction of the penis.

Suprapubic (SP) skin pedicle flap

The fasciocutaneous tissue from the midline SP area is also a possible option as a pedicled flap for the construction of the neophallus. The 14x12cm flap is created by dissecting the SP tissue and is separated from the anterior abdominal wall. The flap is then tubularized and used to reconstruct the neophallus, while maintaining blood supply from the local SP perforator vasculature (5). A great disadvantage of this technique is that innervation is not preserved, making the phallus insensate (5).

Groin (G) pedicle flap

The pedicled groin flap is created by dissecting a rectangular skin flap below the inguinal ligament, which is rotated 180o and used to create a phallus. Vasculature is preserved and is offered by the superficial circumflex iliac artery perforator branches, but, unfortunately, innervation is not preserved (5).

Institutional Repository - Library & Information Centre - University of Thessaly
15/10/2023 05:08:07 EEST - 167.114.118.212

C. Glansplasty

Glansplasty is an aesthetic surgical intervention aiming for the optimal aesthetic result of the created male genitalia (5). As illustrated in Figure 9, there are three techniques described by Garcia et al.

D. Penile and testicular prosthesis

Erectile function after phalloplasty can be achieved, based on knowledge gained through treatment of erectile dysfunction in cisgender men, through the implementation of inflatable penile prosthesis. Patient should not undergo this procedure until after phalloplasty. Furthermore, recurrent urethral strictures or/and fistulas are a definitive contraindication for this procedure (5).

As mentioned above, scrotoplasty is performed by preparing and suturing labia majora in the midline and can be accompanied with testicular prostheses, to achieve optimal aesthetic result (102).

E. Preoperative considerations

In the same approach as in MTF individuals, patients should be holistically evaluated preoperatively. Control of all preexisting medical conditions, which may affect intraoperative and postoperative results, should be achieved; diabetes mellitus control, smoking cessation and DVT prophylaxis (98). Testosterone should be discontinued 2 weeks prior surgery and restarted when patient is mobilized (114). Permanent hair removal on the donor site area should precede any intervention to ensure the neourethra and neophallus lack hair that will complicate the surgical results (102). Lastly, before hysterectomy, all patients should be informed about the option of oocyte or embryo freezing (4).

Institutional Repository - Library & Information Centre - University of Thessaly
15/10/2023 05:08:07 EEST - 167.114.118.212

Complications

FTM GAS complications can be briefly divided in three groups: urinary complications, flap complications and prosthesis complications. Urinary complications arise from the changes in the urinary tract anatomy (112). In metoidioplasty, complication rates reach 37%, with post-void dripple or/and spraying stream to be present in about 33% of the patients (102). Urethral fistulas complicate 5-23% of cased, but only 50% require further surgical treatment (115, 116). In phalloplasty, the most common complication is urethral stricture, which affects about half patients, occurs at the anastomotic site, and usually requires surgical management (102). Flap complications are nowadays a problem that seems to disappear. Survival rates of free flaps reach 98% and pedicled flap loss is documented to be rare (102). Lastly, although prosthetics in GAS surgery come with great satisfaction rates, they come with high complication rates (5, 112). Infection and mechanical failure are the most common prosthesis-related complications (5).

Institutional Repository - Library & Information Centre - University of Thessaly
15/10/2023 05:08:07 EEST - 167.114.118.212

6. Conclusion

Genital Gender Affirming Surgery is a field of medicine that requires a holistic and multidisciplinary approach of each patient. The need of hormonal and surgical interventions arises from the need of treating Gender Dysphoria. The course of treatment has been studied and is strictly regulated by experts in transgender medicine who have established strict criteria both for the diagnosis, as well as the treatment approaches of GD. Through the course of time, there have been a lot of surgical approaches for genital GAS but literature lacks large and multi-center studies in epidemiology and follow-up of transgender individuals.

Institutional Repository - Library & Information Centre - University of Thessaly
15/10/2023 05:08:07 EEST - 167.114.118.212

7. References

1. Fisk NM. Editorial: Gender dysphoria syndrome--the conceptualization that liberalizes indications for total gender reorientation and implies a broadly based multi-dimensional rehabilitative regimen. West J Med. 1974 May;120(5):386-91. PMID: 4839483; PMCID: PMC1130142.
2. Bockting W, Coleman E, De Cuypere G. Care of transsexual persons. N Engl J Med. 2011 Jun 30;364(26):2559-60; author reply 2560. doi: 10.1056/NEJMc1104884. PMID: 21714669.
3. Reisman T., Dacarett-Galeano D., Goldstein Z. (2019). Transgender Care and Medical Education. In: Poretsky, L., Hembree, W. (eds) Transgender Medicine. Contemporary Endocrinology. Humana Press, Cham. https://doi.org/10.1007/978-3-030-05683-4_14
4. World Professional Association for Transgender Health. (2012). *Standards of Care for the Health of Transsexual, Transgender, and Gender Nonconforming People* [7thVersion]. https://www.wpath.org/publications/soc
5. Smith & Tanagho's General Urology, Nineteenth Edition, McGraw-Hill Education, 2020
6. Krafft-Ebing, R. v. Psychopathia Sexualis. (B. King, Trans.). Burbank: Bloat Books; 1906, tr. 1999.
7. Frey JD, Poudrier G, Thomson JE, Hazen A. A Historical Review of Gender-Affirming Medicine: Focus on Genital Reconstruction Surgery. J Sex Med 2017;14:991–1002. doi: 10.1016/j.jsxm.2017.06.007
8. Beemyn G. "A Presence in the Past: A Transgender Historiography." Journal of Women's History, vol. 25 no. 4, 2013, p. 113-121. Project MUSE, doi:10.1353/jowh.2013.0062.
9. Reicherzer S. Evolving language and understanding in the historical development of the gender identity disorder diagnosis. J LGBT Issues Couns 2008;2:326-347. doi: 10.1080/15538600802502035
10. Meyerowitz J. How sex changed: A history of transsexuality in the United States. Harvard University Press; 2004.
11. Beemyn G. Transgender history in the United States. In: Erickson-Schroth L, ed. Trans bodies, trans selves: a resource for the transgender community. New York: Oxford University Press; 2011. p. 1-49.
12. Benjamin H. The transsexual phenomenon. Trans N Y Acad Sci 1967;29:428-430.
13. Nokoff NJ. Medical Interventions for Transgender Youth. [Updated 2022 Jan 19]. In: Feingold KR, Anawalt B, Boyce A, et al., editors. Endotext [Internet]. South Dartmouth (MA): MDText.com, Inc.; 2000-. Available from: https://www.ncbi.nlm.nih.gov/books/NBK577212/?report=classic
14. Association AP. Diagnostic and statistical manual of mental disorders (DSM-5®). American Psychiatric Pub.
15. Hembree WC, Cohen-Kettenis PT, Gooren L, Hannema SE, Meyer WJ, Murad MH, Rosenthal SM, Safer JD, Tangpricha V. T'Sjoen GG. Endocrine Treatment of Gender-Dysphoric/Gender-Incongruent Persons: An Endocrine Society Clinical Practice Guideline. J Clin Endocrinol Metab. 2017;102:3869–3903.
16. Winter S, Diamond M Green J, et al. Transgender people: health at the margins of soicety. Lancet. 2016;388(10042):390–400. doi: 10.1016/ S0140-6736(16)00683-8.
17. Schechter S. L. Gender Confirmation Surgery: Principles and Techniques for an Emerging Field. Springer Cham. doi: 10.1007/978-3-030-29093-1
18. Walinder J. Incidence and sex ratio of transsexualism in Sweden. Br J Psychiatry. 1971;119:195–6. https:// doi.org/10.1192/bjp.119.549.195.
19. Hoenig J, Kenna JC. The prevalence of transsexualism in England and Wales. Br J Psychiatry. 1974;124:181–90.

Institutional Repository - Library & Information Centre - University of Thessaly
15/10/2023 05:08:07 EEST - 167.114.118.212

20. Bakker A, Van Kesteren PJM, Gooren LJG, Bezemer PD. The prevalence of transsexualism in the Netherlands. Acta Psychiatrica Scandinavia. 1993;87(4):237–8. https://doi. org/10.1111/j.1600-0447.1993.tb03364.x.
21. Eklund PLE, Gooren LJG, Bezemer PD. Prevalence of transsexualism in the Netherlands. Br J Psychiatry. 1988;152:638–40. https://doi.org/10.1192/ bjp.152.5.638.
22. Van Kesteren PJ, Gooren LJ, Megens JA. An epidemiological and demographic study of transsexuals in the Netherlands. Arch Sex Behav. 1996;25(6):589–600. https://doi.org/10.1007/BF02437841.
23. Weitze C, Osburg S. Transsexualism in Germany: empirical data on epidemiology and application of the German Transsexuals' act during its first ten years. Arch Sex Behav. 1996;25(4):409–25. https://doi. org/10.1007/BF02437583.
24. De Cuypere G, Van Hemelrijck M, Michel A, Carael B, Heylens G, Rubens R, Monstrey S. Prevalence and demography of transsexualism in Belgium. Eur Psychiatry. 2007;22(3):137–41. https://doi. org/10.1016/j.eurpsy.2006.10.002.
25. Tsoi WF. The prevalence of transsexualism in Singapore. Acta Psychiatrica Scandinavia. 1988;78:501–4. https://doi.org/10.1111/j.1600-0447.1988.tb06373.x.
26. Olyslager F, Conway L. On the calculation of the prevalence of transsexualism. In: Paper presented at the world professional Association for Transgender Health 20th international symposium. Chicago; 2007.
27. Flores AR, Herman JL, Gates GJ, Brown TNT. (2016). How Many Adults Identify as Transgender in the United States? Retrieved 1/31/2018, from the Williams Institute from website. https://williamsinstitute.law.ucla.edu/wp-content/uploads/How- Many-Adults-Identifyas-Transgender-in-the-United-States.pdf Study examining the number of invididuals identifying as transgender.
28. Dhejne C, Öberg K, Arver S, Landén M. An analysis of all applications for sex reassignment surgery in Sweden, 1960–2010: prevalence, incidence, and regrets. Arch Sex Behav. 2014;43(8):1535–45.
29. Arcelus J, Bouman WP, Van Den Noortgate W, Claes L, Witcomb G, Fernandez-Aranda F. Systematic review and meta-analysis of prevalence studies in transsexualism. Eur Psychiatry. 2015 Sep;30(6):807-15. doi: 10.1016/j.eurpsy.2015.04.005. Epub 2015 May 26. PMID: 26021270.
30. Zucker KJ. Epidemiology of gender dysphoria and transgender identity. Sex Health. 2017 Oct;14(5):404-411. doi: 10.1071/SH17067. PMID: 28838353.
31. Zucker KJ, Bradley SJ, Owen-Anderson A, Kibblewhite SJ, Wood H, Singh D, Choi K. Demographics, behavior problems, and psychosexual characteristics of adolescents with gender identity disorder or transvestic fetishism. J Sex Marital Ther. 2012;38(2):151-89. doi: 10.1080/0092623X.2011.611219. PMID: 22390530.
32. Conron KJ, Scott G, Stowell GS, Landers SJ. Transgender health in Massachusetts: results from a household probability sample of adults. Am J Public Health. 2012 Jan;102(1):118-22. doi: 10.2105/AJPH.2011.300315. Epub 2011 Nov 28. PMID: 22095354; PMCID: PMC3490554.
33. Claahsen-van der Grinten H, Verhaak C, Steensma T, Middelberg T, Roeffen J, Klink D. Gender incongruence and gender dysphoria in childhood and adolescence-current insights in diagnostics, management, and follow-up. Eur J Pediatr. 2021 May;180(5):1349-1357. doi: 10.1007/s00431-020-03906-y. Epub 2020 Dec 18. PMID: 33337526; PMCID: PMC8032627.
34. Zucker KJ, Bradley SJ, Owen-Anderson A, Kibblewhite SJ, Cantor JM. Is gender identity disorder in adolescents coming out of the closet? J Sex Marital Ther. 2008;34(4):287-90. doi: 10.1080/00926230802096192. PMID: 18576228.
35. Guillamon A, Junque C, Gómez-Gil E. A Review of the Status of Brain Structure Research in Transsexualism. Arch Sex Behav. 2016 Oct;45(7):1615-48. doi: 10.1007/s10508-016-0768-5. Epub 2016 Jun 2. PMID: 27255307; PMCID: PMC4987404.

Institutional Repository - Library & Information Centre - University of Thessaly
15/10/2023 05:08:07 EEST - 167.114.118.212

36. Schneider HJ, Pickel J, Stalla GK. Typical female 2nd–4th finger length (2D:4D) ratios in male-to-female transsexuals-possible implications for prenatal androgen exposure. Psychoneuroendocrinol. 2006;31(2):265–9.
37. Green R. Family co-occurrence of “gender dysphoria”: ten siblings or parent-child pairs. Arch Sex Beh. 2000;29(5):499–507.
38. Gomez-Gil E, Esteva I, Almaraz MC, et al. Familiality of gender identity disorder in non-twin siblings. Arch Sex Beh. 2010;39(2):265–9.
39. Henningsson S, Westberg L, Nilsson S, et al. Sex steroid-related genes and male-to-female transsexualism. Psychoneuroendocrino. 2005;30(7):657–64.
40. Bentz EK, Hefler LA, Kaufman U, et al. A polymorphism of the CYP17 gene related to sex steroid metabolism is associated with female-to-male but not male-to-female transsexualism. Fertil Steril. 2008;90(1):56–9.
41. Hare L, Bernard P, Sanchez FJ, et al. Androgen receptor length polymorphism associated with male-to-female transsexualism. Biol Psychiatry. 2009;65:93–6.
42. Phelps VR. Relative index finger length as a sex-influenced train in man. Am J Hum Gen. 1952;4:72–89.
43. Garn SM, Burdi AR, Babler WJ, et al. Early prenatal attainment of adult metacarpal-phalangeal rankings and proportions. Am J Phys Anthro. 1975;43: 327–32.
44. Manning JT, Fink B, Neave N, et al. The ratio of 2nd to 4th digit length, a predictor of sperm numbers and concentrations of testosterone, luteinizing hormone and oestrogen. Hum Reprod. 1998;13:3000–4.
45. Galis F, Ten Broek C, Van Dongen S, et al. Sexual dimorphism in the prenatal digit ratio (2D:4D). Arch Sex Beh. 2010;39(1):57–62.
46. Siegmann EM, Müller T, Dziadeck I, Mühle C, Lenz B, Kornhuber J. Digit ratio (2D:4D) and transgender identity: new original data and a meta-analysis. Sci Rep. 2020 Nov 9;10(1):19326. doi: 10.1038/s41598-020-72486-6. PMID: 33168880; PMCID: PMC7653965.
47. Dessens AB, Cohen-Kettenis PT, Mellenbergh GJ, et al. Prenatal exposure to anticonvulsants and psychosexual development. Arch Sex Beh. 1999;28:31–44.
48. Angier, N. Size of region of brain may hold crucial clue to transsexuality, a study finds The New York Times November 2; 1995
49. Krujiver FPM, Zhou J, Pool CW, et al. Male-to-female transsexuals have female neuron numbers in a limbic nucleus. J Clin Endocr Met. 2000;85:2034–41.
50. Chung W, De Vries G, Swaab D. Sexual differentiation of the bed nucleus of the stria terminalis in humans may extend into adulthood. J Neurosci. 2002;22(3):1027–33.
51. Zubiaurre-Elorza L, Junque C, Gomez-Gil E, Segovia S, Carrillo B, Rametti G, Guillamon A. Cortical thickness in untreated transsexuals. Cereb Cortex. 2013;23:2855–62.
52. Savic I, Arver S. Sex dimorphism of the brain in male-to-female transsexuals. Cereb Cortex. 2011;23:2855–62.
53. Rametti G, Carrillo B, Gomez-Gil E, Junque C, Segovia S, Gomez A, Guillamon A. White matter microstructure in female to male transsexuals before cross-sex hormonal treatment: a diffusion tensor imaging study. J Psychiatr Res. 2011a;45:199–204.
54. Rametti G, Carrillo B, Gomez-Gil E, Junque C, Zubiarre-Elorza L, Segovia S, Guillamon A. The microstructure of white matter in male to female transsexuals before cross-sex hormonal treatment: a DTI study. J Psychiatr Res. 2011b;45:949–54.
55. Hulshoff Pol HE, Cohen-Kettenis P, Van Haren N, et al. Changing your sex changes your brain: influences of testosterone and estrogen on adult human brain structure. Eur J Endocrinol. 2006;155:S107–11
56. Altinay M, Anand A. Neuroimaging gender dysphoria: a novel psychobiological model. Brain Imaging Behav. 2020 Aug;14(4):1281-1297. doi: 10.1007/s11682-019-00121-8. PMID: 31134582.

Institutional Repository - Library & Information Centre - University of Thessaly
15/10/2023 05:08:07 EEST - 167.114.118.212

57. Butler J. Gender trouble: feminism and the subversion of identity. New York: Routledge; 1990.
58. Reisner SL, Poteat T, Keatley J, Cabral M, Mothopeng T, Dunham E, Holland CE, Max R, Baral SD. Global health burden and needs of transgender populations: a review. Lancet. 2016 Jul 23;388(10042):412-436. doi: 10.1016/S0140-6736(16)00684-X. Epub 2016 Jun 17. PMID: 27323919; PMCID: PMC7035595.
59. Newcomb ME, Hill R, Buehler K, Ryan DT, Whitton SW, Mustanski B. High Burden of Mental Health Problems, Substance Use, Violence, and Related Psychosocial Factors in Transgender, Non-Binary, and Gender Diverse Youth and Young Adults. Arch Sex Behav. 2020 Feb;49(2):645-659. doi: 10.1007/s10508-019-01533-9. Epub 2019 Aug 14. PMID: 31485801; PMCID: PMC7018588.
60. Feldman J, Brown GR, Deutsch MB, Hembree W, Meyer W, Meyer-Bahlburg HF, Tangpricha V, T'Sjoen G, Safer JD. Priorities for transgender medical and healthcare research. Curr Opin Endocrinol Diabetes Obes. 2016 Apr;23(2):180-7. doi: 10.1097/MED.0000000000000231. PMID: 26825469; PMCID: PMC4821501.
61. Meyer IH, Brown TN, Herman JL, Reisner SL, Bockting WO. Demographic characteristics and health status of transgender adults in select U.S. regions: Behavioral Risk Factor Surveillance System, 2014. Am J Public Health. 2017;107(4):582–589. https://doi.org/10.2105/ AJPH.2016.303648.
62. Caceres BA, Jackman KB, Edmondson D, Bockting WO. Assessing gender identity differences in cardiovascular disease in U.S. adults: an analysis of data from the 2014-2017 BRFSS. J Behav Med. 2020;43 (2):329–338. https://doi.org/10.1007/s10865-019-00102-8.
63. Downing JM, Przedworski JM. Health of transgender adults in the U. S., 2014-2016. Am J Prev Med. 2018;55(3):336–344. https://doi.org/ 10.1016/j.amepre.2018.04.045.
64. Alzahrani T, Nguyen T, Ryan A, et al. Cardiovascular disease risk factors and myocardial infarction in the transgender population. Circ Cardiovasc Qual Outcomes. 2019;12(4):e005597. https://doi.org/ 10.1161/CIRCOUTCOMES.119.005597.
65. Suen YT, Chan RCH, Wong EMY. Mental Health of Transgender People in Hong Kong: A Community-Driven, Large-Scale Quantitative Study Documenting Demographics and Correlates of Quality of Life and Suicidality, Journal of Homosexuality, 2018;65:8, 1093-1113, DOI: 10.1080/00918369.2017.1368772
66. Poteat et al. Cardiovascular Disease in a Population-Based Sample of Transgender and Cisgender Adults. Am J Prev Med 2021;000(000):1−8. Doi: 10.1016/j.amepre.2021.05.019
67. Walter J. Meyer III (2009) World Professional Association for Transgender Health's Standards of Care Requirements of Hormone Therapy for Adults with Gender Identity Disorder, International Journal of Transgenderism, 11:2, 127-132, DOI: 10.1080/15532730903008065
68. Green R, Fleming DT. Transsexual Surgery Follow-Up: Status in the 1990s, Annual Review of Sex Research, 1990;1:1, 163-174, DOI: 10.1080/10532528.1990.10559859
69. Coleman E, Bockting W, Botzer M, et al. Standards of care for the health of transsexual, transgender, and gender- nonconforming people, version 7. Int J Transgend 2012; 13:165-232.
70. Hess J, Rossi Neto R, Panic L, et al. Satisfaction with male-to-female gender reassignment surgery. Dtsch Arztebl Int 2014; 111:795-801.
71. De Cuypere G, T'Sjoen G, Beerten R, et al. Sexual and physical health after sex reassignment surgery. Arch Sex Behav 2005; 34:679-690.
72. de Vries A, McGuire JK, Steensma TD, et al. Young adult psychological outcome after puberty suppression and gender reassignment. Pediatrics 2014;134:696-704.
73. Cardoso da Silva D, Schwarz K, Fontanari AMV, et al. WHO- QOL-100 before and after sex reassignment surgery in Brazilian male-to-female transsexual individuals. J Sex Med 2016;13:988-993.

Institutional Repository - Library & Information Centre - University of Thessaly
15/10/2023 05:08:07 EEST - 167.114.118.212

74. Lawrence AA. Patient-reported complications and functional outcomes of male-to-female sex reassignment surgery. Arch Sex Behav 2006;35:717-727.
75. Ruppin U, Pfäfflin F. Long-term follow-up of adults with gender identity disorder. Arch Sex Behav 2015;44:1321-1329.
76. Safa B, Lin WC, Salim AM, Deschamps-Braly JC, Poh MM. Current Concepts in Feminizing Gender Surgery. Plast Reconstr Surg. 2019 May;143(5):1081e-1091e. doi: 10.1097/PRS.0000000000005595. PMID: 31033837.
77. Hadj-Moussa M, Ohl DA, Kuzon WM Jr. Feminizing Genital Gender-Confirmation Surgery. Sex Med Rev. 2018 Jul;6(3):457-468.e2. doi: 10.1016/j.sxmr.2017.11.005. Epub 2018 Feb 14. PMID: 29454634.
78. Beek TF, Cohen-Kettenis PT, Kreukels BP. Gender incongruence/gender dysphoria and its classification history. Int Rev Psychiatry. 2016;28(1):5-12. doi: 10.3109/09540261.2015.1091293. Epub 2015 Nov 19. PMID: 26782319.
79. Riverdale J. A brief history of FTM trans civilization. Published October 29, 2012. Available at: http://transguys.com/ features/ftm-trans-history. Accessed October 24, 2016.
80. Magnus Hirschfeld—the father of transgenderism. Available at: http://www.gendernetwork.com/Magnus-Hirschfeld.html#. WW4ywIQrKJA. Accessed January 24, 2017.
81. Hage JJ, Karim RB, Laub DR Sr. On the origin of pedicled skin inversion vaginoplasty: life and work of Dr Georges Burou of Casablanca. Ann Plast Surg 2007;59:723-729.
82. Money J, Brennan JG. Sexual dimorphism in the psychology of female transsexuals. J Nerv Ment Dis 1968;147:487-499.
83. Morrison SD, Satterwhite T, Grant DW, et al. Long-term outcomes of rectosigmoid neocolporrhaphy in male-to- female gender reassignment surgery. Plast Reconstr Surg 2015;136:386-394.
84. Eldh J. Construction of a neovagina with preservation of the glans penis as a clitoris in male transsexuals. Plast Reconstr Surg. 1993 Apr;91(5):895-900; discussion 901-3. PMID: 8460193.
85. Buncamper ME, van der Sluis WB, van der Pas RSD, et al. Surgical outcome after penile inversion vaginoplasty: A retrospective study of 475 transgender women. Plastic and Reconstructive Surgery, 138(5), 999–1007. doi:10.1097/PRS.0000000000002684
86. van der Sluis WB, Steensma TD, Bouman MB. Orchiectomy in transgender individuals: A motivation analysis and report of surgical outcomes, International Journal of Transgender Health. 2020; 21:2, 176-181, DOI: 10.1080/26895269.2020.1749921
87. Schwartz AR, Moravek MB. Reproductive potential and fertility preservation in transgender and nonbinary individuals. Curr Opin Obstet Gynecol. 2021 Aug 1;33(4):327-334. doi: 10.1097/GCO.0000000000000729. PMID: 34173770.
88. Hadj-Moussa M, Ohl DA, Kuzon WM Jr. Feminizing Genital Gender-Confirmation Surgery. Sex Med Rev. 2018 Jul;6(3):457-468.e2. doi: 10.1016/j.sxmr.2017.11.005. Epub 2018 Feb 14. PMID: 29454634.
89. Salim A, Poh M. Gender-Affirming Penile Inversion Vaginoplasty. Clin Plast Surg. 2018 Jul;45(3):343-350. doi: 10.1016/j.cps.2018.04.001. PMID: 29908622.
90. Clement P, Giuliano F. Anatomy and physiology of genital organs - men. Handb Clin Neurol. 2015;130:19-37. doi: 10.1016/B978-0-444-63247-0.00003-1. PMID: 26003237.
91. WESSON MB. What are Buck's and Colles' fasciae? J Urol. 1953 Sep;70(3):503-11. doi: 10.1016/s0022-5347(17)67939-4. PMID: 13085510.
92. Britannica, The Editors of Encyclopaedia. "scrotum". *Encyclopedia Britannica*, 20 Jun. 2018, https://www.britannica.com/science/scrotum. Accessed 28 August 2022.

Institutional Repository - Library & Information Centre - University of Thessaly
15/10/2023 05:08:07 EEST - 167.114.118.212

93. Ting J, Bowers M. (2020). Penile Inversion Vaginoplasty. In: Schechter, L. (eds) Gender Confirmation Surgery. Springer, Cham. https://doi.org/10.1007/978-3-030-29093-1_14
94. Reed HM. Aesthetic and functional male to female genital and perineal surgery: feminizing vaginoplasty. Semin Plast Surg. 2011 May;25(2):163-74. doi: 10.1055/s-0031-1281486. PMID: 22547974; PMCID: PMC3312144.
95. Schechter L S.15—Surgery for gender identity disorder. 3rd ed. Philadelphia: Elsevier 2013.
96. Bouman MB, van Zeijl MC, Buncamper ME, Meijerink WJ, van Bodegraven AA, Mullender MG. Intestinal vaginoplasty revisited: a review of surgical techniques, complications, and sexual function. J Sex Med. 2014 Jul;11(7):1835-47. doi: 10.1111/jsm.12538. Epub 2014 Apr 4. PMID: 24697986.
97. Bouman MB, van der Sluis WB, van Woudenberg Hamstra LE, Buncamper ME, Kreukels BPC, Meijerink WJHJ, Mullender MG. Patient-Reported Esthetic and Functional Outcomes of Primary Total Laparoscopic Intestinal Vaginoplasty in Transgender Women With Penoscrotal Hypoplasia. J Sex Med. 2016 Sep;13(9):1438-1444. doi: 10.1016/j.jsxm.2016.06.009. Epub 2016 Jul 27. PMID: 27475240.
98. Wijeysundera DN, Sweitzer B-J. Preoperative evaluation. In: Miller, ed. Miller's anesthesia. 8th ed. Philadelphia: Elsevier; 2015. p. 1085-1155.
99. Wilczynski C, Emanuele MA. Treating a transgender patient: overview of the guidelines. Postgrad Med. 2014 Nov;126(7):121-8. doi: 10.3810/pgm.2014.11.2840. PMID: 25387220.
100. Horbach SE, Bouman MB, Smit JM, Özer M, Buncamper ME, Mullender MG. Outcome of Vaginoplasty in Male-to-Female Transgenders: A Systematic Review of Surgical Techniques. J Sex Med. 2015 Jun;12(6):1499-512. doi: 10.1111/jsm.12868. Epub 2015 Mar 26. PMID: 25817066.
101. Raigosa M, Avvedimento S, Yoon TS, Cruz-Gimeno J, Rodriguez G, Fontdevila J. Male-to-Female Genital Reassignment Surgery: A Retrospective Review of Surgical Technique and Complications in 60 Patients. J Sex Med. 2015 Aug;12(8):1837-45. doi: 10.1111/jsm.12936. Epub 2015 Jul 2. PMID: 26139337.
102. Hadj-Moussa M, Agarwal S, Ohl DA, Kuzon WM Jr. Masculinizing Genital Gender Confirmation Surgery. Sex Med Rev. 2019 Jan;7(1):141-155. doi: 10.1016/j.sxmr.2018.06.004. Epub 2018 Aug 16. PMID: 30122339.
103. Deschamps-Braly JC, Sacher CL, Fick J, Ousterhout DK. First Female-to-Male Facial Confirmation Surgery with Description of a New Procedure for Masculinization of the Thyroid Cartilage (Adam's Apple). Plast Reconstr Surg. 2017 Apr;139(4):883e-887e. doi: 10.1097/PRS.0000000000003185. PMID: 28350659.
104. Schultheiss D, Gabouev AI, Jonas U. Nikolaj A. Bogoraz (1874-1952): pioneer of phalloplasty and penile implant surgery. J Sex Med. 2005 Jan;2(1):139-46. doi: 10.1111/j.1743-6109.2005.20114.x. PMID: 16422917.
105. Durfee R, Rowland W. Penile substitution with clitoral enlargement and urethral transfer. In: Laub DR, Gandy P, editors. Proceedings of the second interdisciplinary symposium on gender dysphoria syndrome. Palo Alto: Stanford University Press; 1973. p. 181–3.
106. Bateman C. World's first successful penis transplant at Tygerberg Hospital. S Afr Med J. 2015 Apr;105(4):251-2. doi: 10.7196/samj.9602. PMID: 26294859.
107. Laub DR, Eicher W, Laub DR II, Hentz VR. Penis construction in female-to-male transsexuals. In: Eicher W, Kubli F, Herms V, editors. Plastic surgery in the sexually handicapped. Berlin: Springer; 1989. p. 113–28.
108. Pauls RN. Anatomy of the clitoris and the female sexual response. Clin Anat. 2015 Apr;28(3):376-84. doi: 10.1002/ca.22524. Epub 2015 Mar 2. PMID: 25727497.

Institutional Repository - Library & Information Centre - University of Thessaly
15/10/2023 05:08:07 EEST - 167.114.118.212

109. Djordjevic ML, Bizic MR. Comparison of two different methods for urethral lengthening in female to male (metoidioplasty) surgery. J Sex Med. 2013 May;10(5):1431-8. doi: 10.1111/jsm.12108. Epub 2013 Feb 27. PMID: 23444841.
110. Hage J, De Graaf FH. Addressing the ideal requirements by free flap phalloplasty: some reflections on refinements of technique. Microsurgery 1993;14:592-598.
111. Chang TS, Hwang WY. Forearm flap in one-stage reconstruction of the penis. Plast Reconstr Surg. 1984 Aug;74(2):251-8. doi: 10.1097/00006534-198408000-00014. PMID: 6463150.
112. Safa B, Lin WC, Salim AM, Deschamps-Braly JC, Poh MM. Current Concepts in Masculinizing Gender Surgery. Plast Reconstr Surg. 2019 Apr;143(4):857e-871e. doi: 10.1097/PRS.0000000000005453. PMID: 30921151.
113. Song YG, Chen GZ, Song YL. The free thigh flap: a new free flap concept based on the septocutaneous artery. Br J Plast Surg. 1984 Apr;37(2):149-59. doi: 10.1016/0007-1226(84)90002-x. PMID: 6713155.
114. Schechter LS. Surgical management of the transgender patient. 1st ed. Philadelphia,PA: Elsevier; 2017.
115. Stojanovic B, Bizic M, Bencic M, et al. One-stage gender- confirmation surgery as a viable surgical procedure for female-to-male transsexuals. J Sex Med 2017;14:741-746.
116. Hage JJ, van Turnhout AA. Long-term outcome of meta- idoioplasty in 70 female-to-male transsexuals. Ann Plast Surg 2006;57:312-316.

Institutional Repository - Library & Information Centre - University of Thessaly
15/10/2023 05:08:07 EEST - 167.114.118.212

8. Appendix

Tables

Table 1: Terminology – Adapted from Endocrine Society Clinical Practice Guideline 2017 (15)

Term	Meaning	Note
Sex	Attributes that characterize biologic maleness or femaleness; factors that influence sex include sex chromosomes, gonads, sex steroids, internal reproductive structures, external genitalia, secondary sex characteristics	In use
Gender (role)	Behaviors, attitudes, and personality trait that a society (in a given culture and historical period) designates as masculine or feminine and/or that society associates with the typical social role of men or women	In use
Agender	A person with very little or no connection to the traditional systems of gender; existing without gender	In use
Cisgender	A person whose gender identity aligns with biologic sex	In use
Sexual orientation	Physical and emotional attraction to others. Gender identity and sexual orientation are not the same	In use
Gender identity	One's internal, deeply held sense of gender; not visible to others	In use
Gender nonconformity/ Gender non-binary	A person whose gender identity is neither male nor female, both male and female or some combination of genders	In use
Gender dysphoria	Distress experienced when gender identity and body are not congruent. Defined in the DSM-5, which replaced "gender identity disorder" in the DSM-IV	In use
Transgender person	Gender identity differs from sex designated at birth	In use
Transsexual person	Old term used to describe what is nowadays described as Transgender	Not in use – *pathologising term*
Transgender female	Individuals designated male at birth who identify and live as women	In use
Transgender male	Individuals designed female at birth who identify and live as men	In use
Gender identity disorder	Old term (in DSM-IV) that describes what nowadays is called GD	Not in use – *old DSM term*
Gender-affirming surgery (GAS)	Surgery or surgerical procedures a person udergoes to align one's body with one's gender identity	In use
Gender reassignment surgery	Old term for GAS	Not in use – *older term*
Transvestile, "cross-dresser", etc	Old pathologising terms for Transgender people	Not in use – *pathologising term*

Institutional Repository - Library & Information Centre - University of Thessaly
15/10/2023 05:08:07 EEST - 167.114.118.212

Table 2: Overview of surgical procedures

Feminising procedures	Masculinising facial surgery Thyroid-cartilage reduction Vocal cord surgery Breast augmentation Feminising genital procedures Body contouring (with filling agents/liposuction/lipofilling)
Masculinising procedures	Masculinising facial surgery Bilateral mastectomy Masculinising genital procedures

Figures

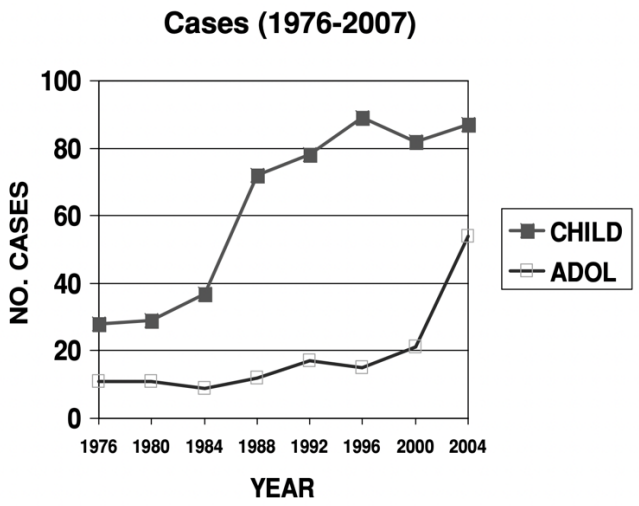

Figure 1: Number of children and adolescents referrals to Zucker's team from 1976 to 2007. Source: Zucker et al. Is gender identity disorder in adolescents coming out of the closet? J Sex Marital Ther. 2008;34(4):287-90. doi: 10.1080/00926230802096192. PMID: 18576228.

Institutional Repository - Library & Information Centre - University of Thessaly
15/10/2023 05:08:07 EEST - 167.114.118.212

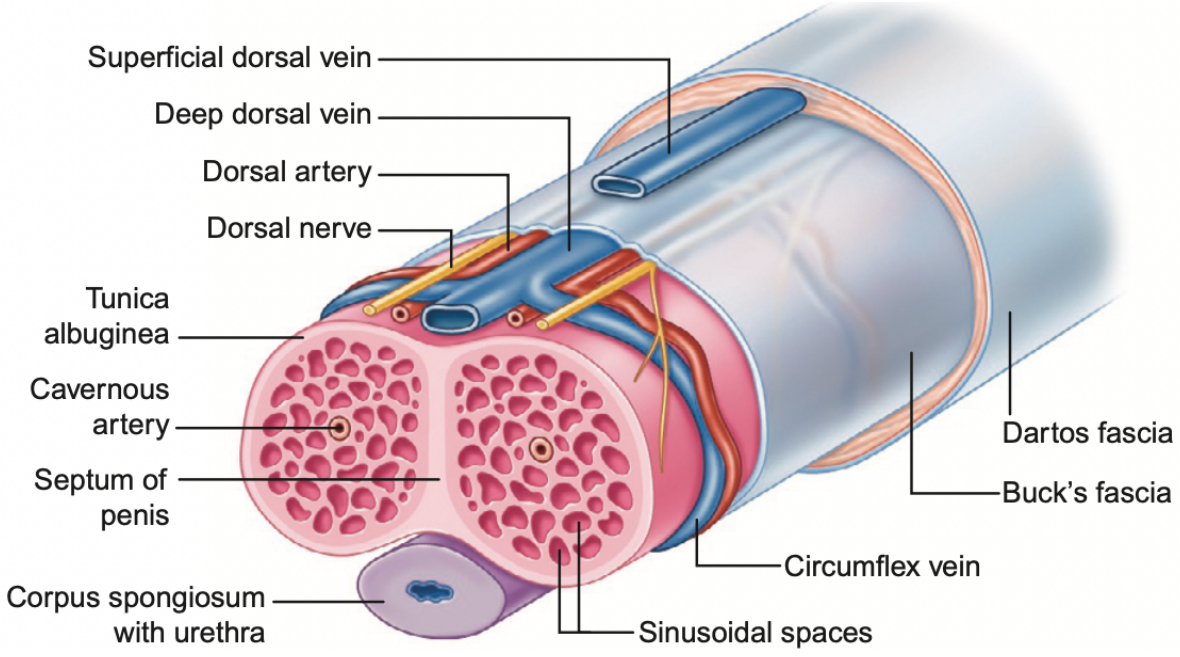

Figure 2: Anatomy, vasculature and innervation of corpora cavernosa and corpus spongiosum. Source: Standring S (2009). Gray's Anatomy, 40th edn. Churchill Livingstone, London.

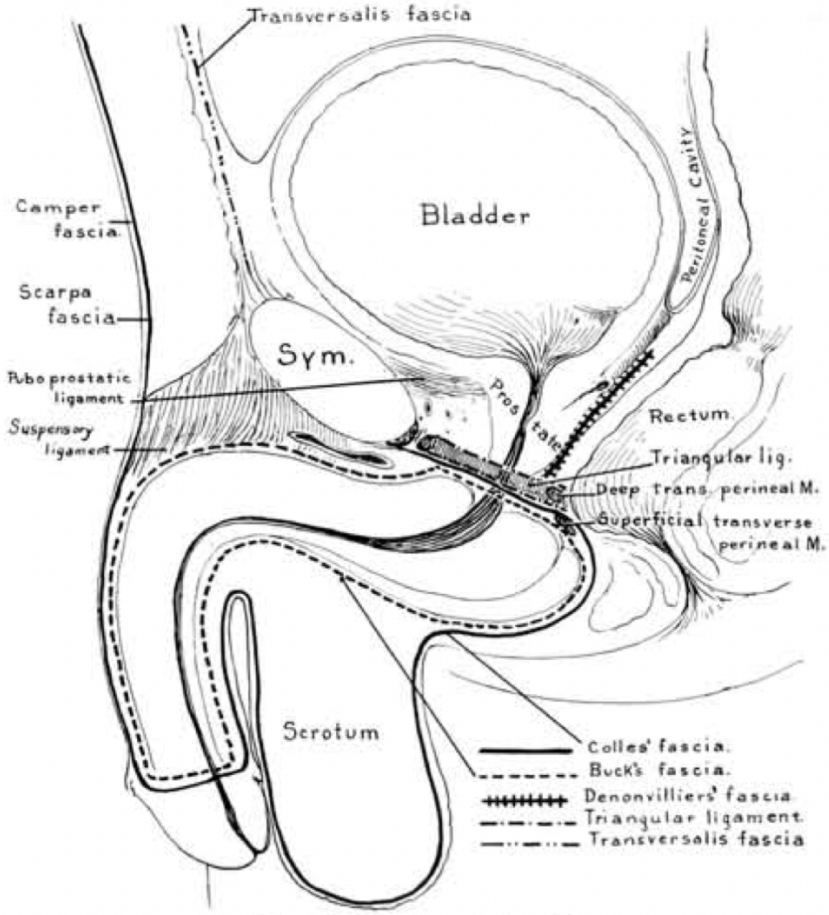

Figure 3: Illustration of fascia and ligaments of male genitalia and pelvic area. Source: WESSON MB. What are Buck's and Colles' fasciae? J Urol. 1953 Sep;70(3):503-11.

Institutional Repository - Library & Information Centre - University of Thessaly
15/10/2023 05:08:07 EEST - 167.114.118.212

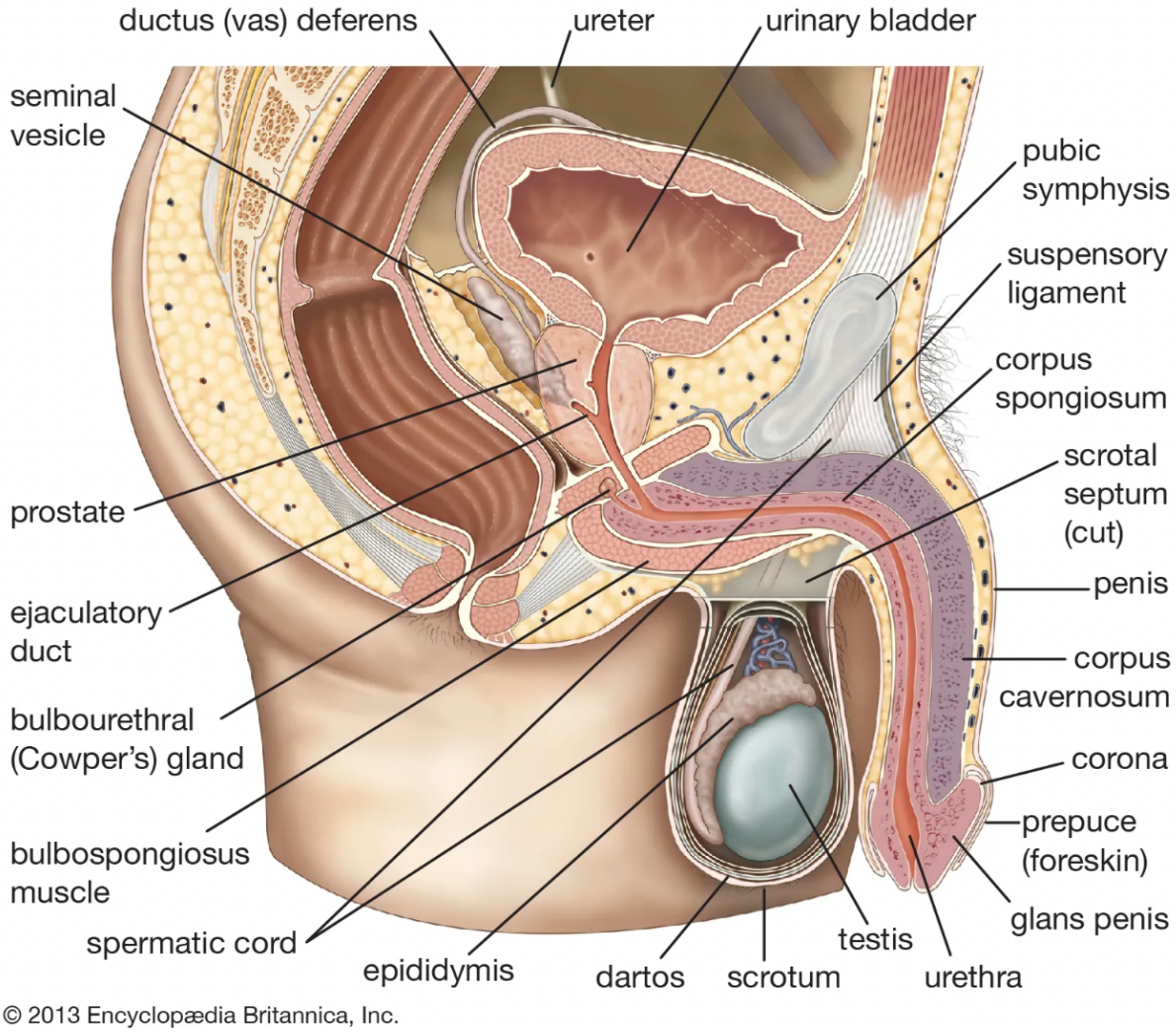

Figure 4: Male anatomy.
Source: Britannica, The Editors of Encyclopaedia. "scrotum". *Encyclopedia Britannica*, 20 Jun. 2018, https://www.britannica.com/science/scrotum. Accessed 28 August 2022.

Institutional Repository - Library & Information Centre - University of Thessaly
15/10/2023 05:08:07 EEST - 167.114.118.212

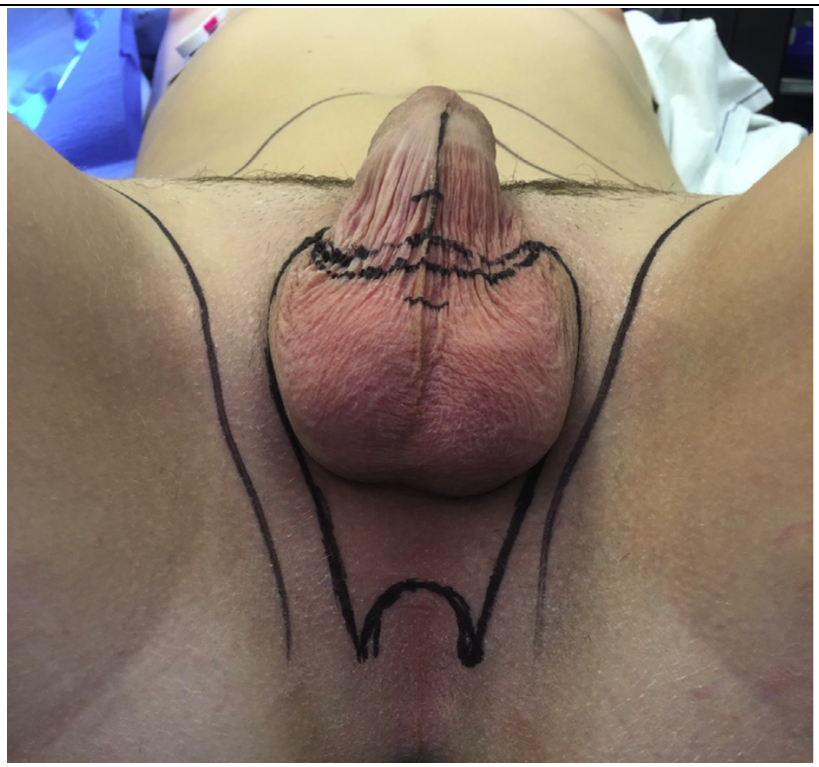

Figure 5: Posterior view of preoperative skin marks for planning incision and formation of skin flaps.
Source: Salim A, Poh M. Gender-Affirming Penile Inversion Vaginoplasty. Clin Plast Surg. 2018 Jul;45(3):343-350.

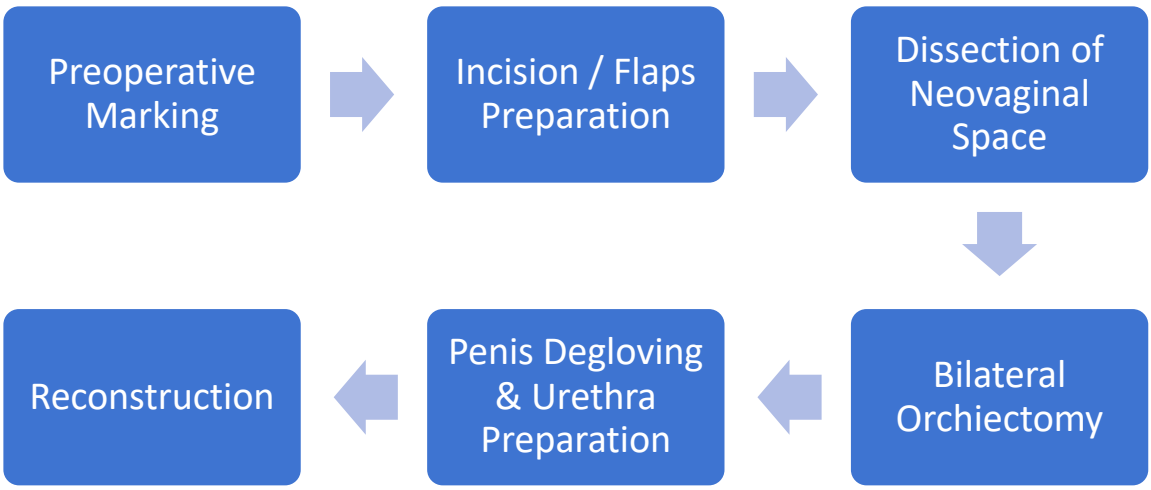

Figure 6: Steps of Vaginoplasty

Institutional Repository - Library & Information Centre - University of Thessaly
15/10/2023 05:08:07 EEST - 167.114.118.212

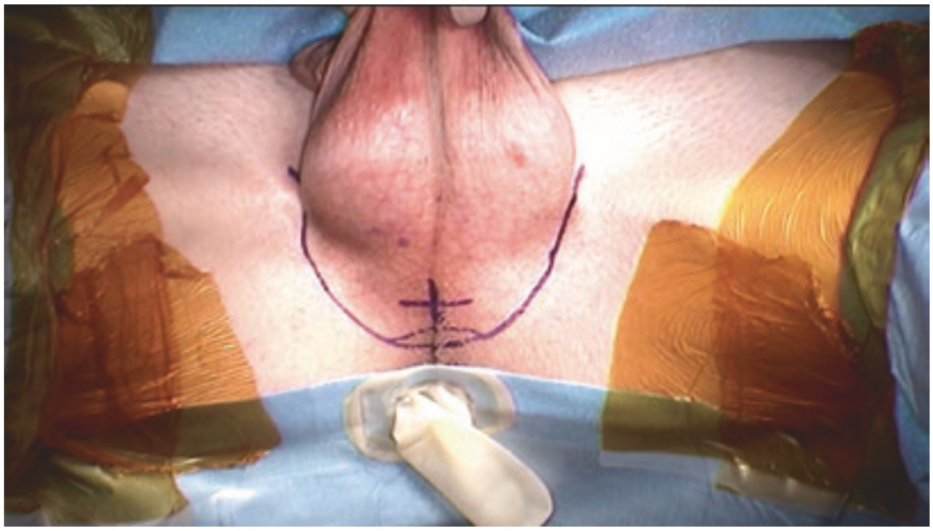

Figure 7: Illustration of the position of the neovaginal canal space.
Source: Ting J, Bowers M. (2020). Penile Inversion Vaginoplasty. In: Schechter, L. (eds) Gender Confirmation Surgery. Springer, Cham. https://doi.org/10.1007/978-3-030-29093-1_14

Figure 8: Free full-thickness scrotal skin grafts sutured around the vaginal stent.
Source: Ting J, Bowers M. (2020). Penile Inversion Vaginoplasty. In: Schechter, L. (eds) Gender Confirmation Surgery. Springer, Cham. https://doi.org/10.1007/978-3-030-29093-1_14

Institutional Repository - Library & Information Centre - University of Thessaly
15/10/2023 05:08:07 EEST - 167.114.118.212

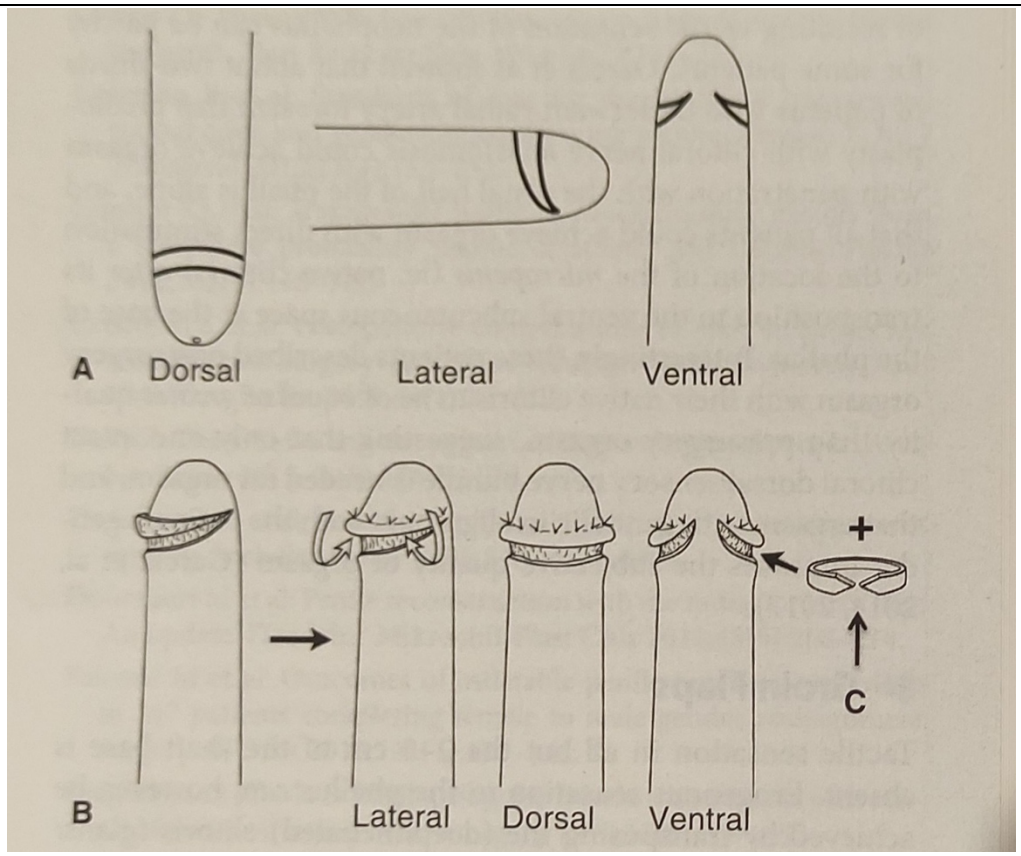

Figure 9: Incision markings (A) and incisions in glansplasty.
Source: Garcia MM, Thomas P, Christofer NA, et al. Genital Gender Affirming Surgery for Transgender Patients. AUA Update Series, 2017; 36: Lesson 5

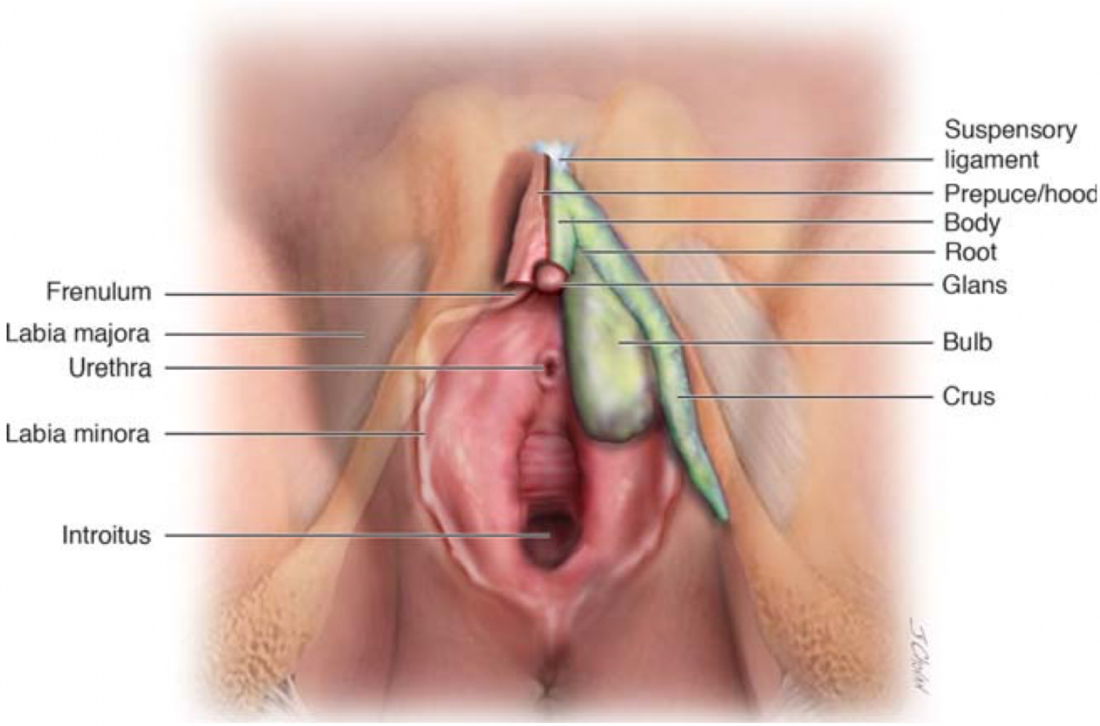

Figure 10: Anatomy of the vulva and clitoris.
Source: Pauls RN. Anatomy of the clitoris and the female sexual response. Clin Anat. 2015 Apr;28(3):376-84. doi: 10.1002/ca.22524. Epub 2015 Mar 2. PMID: 25727497.

Institutional Repository - Library & Information Centre - University of Thessaly
15/10/2023 05:08:07 EEST - 167.114.118.212

Figure 11: Defect of the urethral plate.
Source: Djordjevic ML, Bizic MR. Comparison of two different methods for urethral lengthening in female to male (metoidioplasty) surgery. J Sex Med. 2013 May;10(5):1431-8. doi: 10.1111/jsm.12108. Epub 2013 Feb 27. PMID: 23444841.

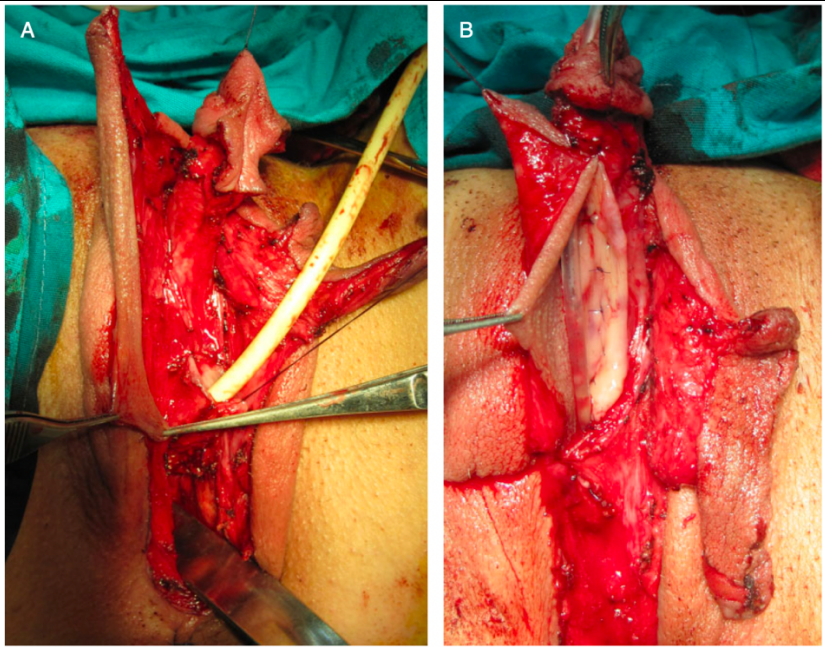

Figure 12: Creation of the urethral tube using fasciocutaneous flaps from labia minora. Joined with buccal mucosa grafts.
Source: Djordjevic ML, Bizic MR. Comparison of two different methods for urethral lengthening in female to male (metoidioplasty) surgery. J Sex Med. 2013 May;10(5):1431-8. doi: 10.1111/jsm.12108. Epub 2013 Feb 27. PMID: 23444841.

Institutional Repository - Library & Information Centre - University of Thessaly
15/10/2023 05:08:07 EEST - 167.114.118.212

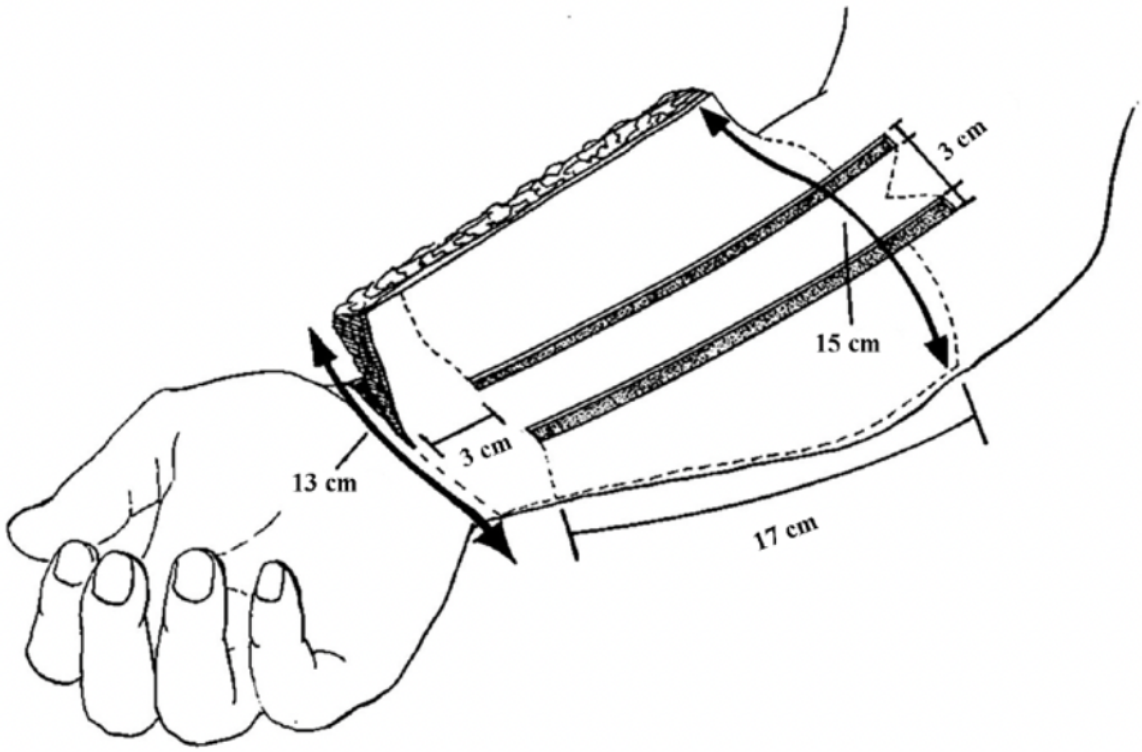

Figure 13: Forearm skin and subcutaneous adipose free flap.
Source: Safa B, Lin WC, Salim AM, Deschamps-Braly JC, Poh MM. Current Concepts in Feminizing Gender Surgery. Plast Reconstr Surg. 2019 May;143(5):1081e-1091e. doi: 10.1097/PRS.0000000000005595. PMID: 31033837.

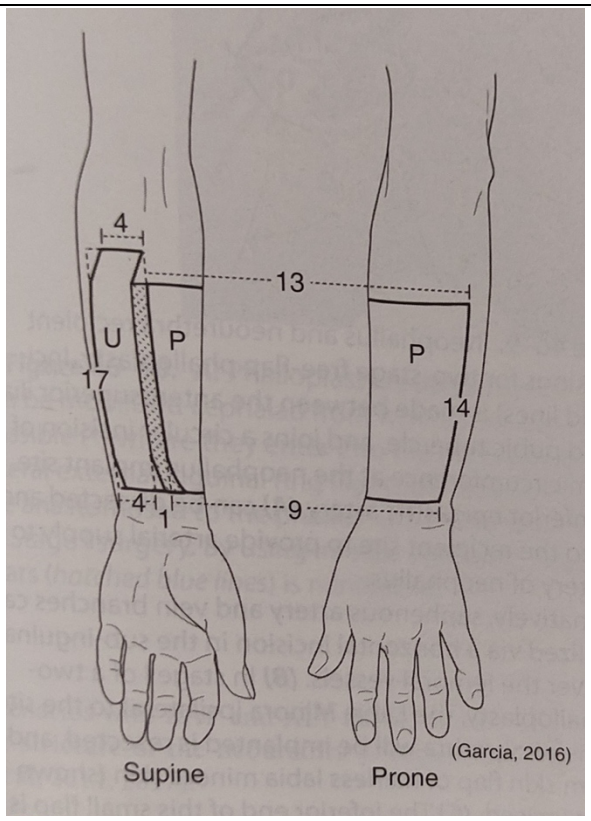

Figure 14: Forearm free flap markings for urethral and penile segment creation.
Source: Garcia MM, Thomas P, Christofer NA, et al. Genital Gender Affirming Surgery for Transgender Patients. AUA Update Series, 2017; 36: Lesson 5

Institutional Repository - Library & Information Centre - University of Thessaly
15/10/2023 05:08:07 EEST - 167.114.118.212