



ΔΙΑΚΡΑΤΙΚΟ
ΔΙΑΤΜΗΜΑΤΙΚΟ
ΠΡΟΓΡΑΜΜΑ
ΜΕΤΑΠΤΥΧΙΑΚΩΝ
ΣΠΟΥΔΩΝ

ΙΑΤΡΙΚΗ ΣΧΟΛΗ
ΠΑΝΕΠΙΣΤΗΜΙΟ ΘΕΣΣΑΛΙΑΣ
σε συνεργασία με το
UNIVERSITÀ DEGLI STUDI
DI GENOVA



Μεταπτυχιακή Διπλωματική Εργασία

**"Η ΕΦΑΡΜΟΓΗ ΤΟΥ ΔΙΕΓΧΕΙΡΗΤΙΚΟΥ
ΥΠΕΡΗΧΟΓΡΑΦΗΜΑΤΟΣ ΚΑΤΑ ΤΗΝ
ΕΝΔΑΡΤΗΡΕΚΤΟΜΗ ΚΑΡΩΤΙΔΑΣ ΩΣ ΜΕΘΟΔΟΣ
ΠΟΙΟΤΙΚΟΥ ΕΛΕΓΧΟΥ: ΣΥΣΤΗΜΑΤΙΚΗ
ΑΝΑΣΚΟΠΗΣΗ ΚΑΙ ΜΕΤΑ-ΑΝΑΛΥΣΗ"**

υπό

ΣΠΥΡΙΔΩΝΟΣ Χ. ΝΙΚΑ

Ειδικευόμενου Αγγειοχειρουργικής

Υπεβλήθη για την εκπλήρωση μέρους των
απαιτήσεων για την απόκτηση του
Διακρατικού Μεταπτυχιακού Διπλώματος Ειδίκευσης
«Υπερηχογραφική Λειτουργική Απεικόνιση για την πρόληψη & διάγνωση των
αγγειακών παθήσεων»

Θεσσαλονίκη, 2019

Επιβλέπων:

Ρούσας Νικόλαος, *Αγγειοχειρουργός, Επιμελητής Β' ΕΣΥ Αγγειοχειρουργικής Κλινικής Πανεπιστημίου Θεσσαλίας, Υπεύθυνος Μονάδος Αναίμακτης Διαγνωστικής Αγγειακών Παθήσεων ΠΓΝ Λάρισας.*

Τριμελής Συμβουλευτική Επιτροπή:

1. Ρούσας Νικόλαος, *Αγγειοχειρουργός, Επιμελητής Β' ΕΣΥ Αγγειοχειρουργικής Κλινικής Πανεπιστημίου Θεσσαλίας, Υπεύθυνος Μονάδος Αναίμακτης Διαγνωστικής Αγγειακών Παθήσεων ΠΓΝ Λάρισας.*
2. Γιαννούκας Αθανάσιος, *Καθηγητής Αγγειοχειρουργικής, Τμήματος Ιατρικής, Πανεπιστημίου Θεσσαλίας.*
3. Κακίσης Ιωάννης, *Καθηγητής Αγγειοχειρουργικής, Τμήματος Ιατρικής, Εθνικού Καποδιστριακού Πανεπιστημίου Αθηνών.*

Τίτλος εργασίας στα αγγλικά:

“The use of Intraoperative Ultrasound during Carotid Endarterectomy as a Quality Control Method: a Systematic Review and Meta-analysis”

Abstract

Carotid Endarterectomy (CEA) is a classic open vascular procedure for treating carotid artery stenosis and preventing stroke. To identify intraoperatively technical defects that could lead to perioperative stroke, a tragic and devastating complication, completion studies have been used. Duplex ultrasonography, with or without color-Doppler, is a safe, fast, easy and cheap imaging modality that could potentially enlighten the surgeon in the face of these technical imperfections and lead to revision of the arterial reconstruction, with possible benefit on the postoperative complications. In this study, a systematic review and meta-analysis is conducted in order to prove whether or not the intraoperative use of the ultrasound as a completion study provides better surgical results with lower complication and recurrent stenosis rates. It reports the overall incidence of findings between 31 papers, the total revision rate, and discusses the benefits of this imaging study. Even, after more than 40 years of completion imaging, no consensus on the worldwide guidelines exists.

Key-Words

Carotid endarterectomy, CEA, carotid artery stenosis, carotid artery occlusive disease, intraoperative, ultrasound, ultrasonography, completion imaging, vascular defects, systematic review, meta-analysis.

Table of contents

Chapter		1:
Introduction.....	5	
1.1 Stroke		
.....	5	
1.2 Carotid Endarterectomy (CEA).....		7
1.3 Vascular		
Defects.....		8
1.4 Intraoperative Ultrasound.....		10
Chapter	2:	Materials and
Methods.....		12
2.1 Inclusion Criteria.....		12
2.2 Search Strategy.....		13
Chapter		3:
Results.....		14
3.1.		General
Results.....		14
3.2. Endpoint 1 – finding rate.....		16
3.3. Endpoint 2 – revision		rate.....18
3.4. Endpoint 3 – 30day stroke, death and MI combined		rate.....20
3.5. Endpoint 4 – recurrent stenosis		rate.....22
3.6. Other Results.....		22
Chapter 4: Discussion.....		23
Chapter 5: Conclusion.....		24
Chapter 6: Reference List.....		25

Chapter 1. Introduction

Chapter 1.1. Stroke

Stroke is one of the leading causes of mortality and morbidity in the world and the accompanying disabilities are a major healthcare and community burden, especially in the financially developed countries. Stroke, or cerebral infarction, is defined as the acute development of neurological symptoms with a focal distribution that is caused by the disruption of blood flow to a brain area (*Figure 1*). It is traditionally and roughly divided to ischemic (due to occlusion of a blood vessel) or hemorrhagic (due to rupture of a blood vessel), and its clinical presentation varies from silent cerebral infarctions that are asymptomatic to devastating, fatal strokes. A transient ischemic attack (TIA) presents itself as a stroke-like entity whose symptoms last less than 24 hours. Patients with TIAs have a significantly higher risk of having a stroke and unfortunately many of them are being undiagnosed.

SIGNS AND SYMPTOMS	VESSEL
Contralateral hemiparesis (leg > face and arm)	Anterior cerebral artery
Contralateral hemiparesis (face and arm > leg)	Middle cerebral artery
Aphasia	Left middle cerebral artery
Monocular blindness (amaurosis fugax)	Internal carotid artery
Diplopia, dysarthria, dysphagia, vertigo, gait imbalance, weakness	Vertebral and basilar arteries


Figure 1:
Stroke symptoms depending on the vessel that is embolised. Carotid thromboembolisation affects the ACA and the MCA or the ocular circulation.

Stroke as an entity was thought to be a result of intracranial pathology until relatively recent years. Even one of the greatest physicians of his era, Sir William Osler, wrote on his “The Principles and Practice of Medicine” in 1909 that stroke was caused mainly by vasospasm and intracranial hemorrhage, without mention of extracranial (carotid or vertebral) occlusive disease¹. Earlier, however, had been two reports connecting stroke and carotid occlusive disease. First, Gowers reported in 1875 a case of a patient with left hemianopsia and right hemiplegia that was found to have carotid artery atheromatous disease². Thirty years later, Chiari in 1905 studied 400 autopsies of patients that had suffered strokes and found evidence of occlusive disease³. It was not nevertheless until 1951 and the work of neurologist Charles Miller Fischer, who published his breakthrough work on occlusion of the

carotid arteries, that carotid artery occlusive disease became strongly associated and recognized as an independent causative factor for stroke^{4,5}.

The incidence of stroke experienced a dramatic rise in the middle of the 20th century, as lifestyle social habits like smoking and unhealthy eating made their appearance due to improved living conditions and income raise in the first world. Tobacco smoking, hyperlipidemia, diabetes mellitus, obesity and arterial hypertension are well established risk factors for cardiovascular disease, as pointed out by the Framingham Heart Study (FHS) and many other Randomized Controlled Trials (RCTs) since then, and the FHS is also the origin of the term “risk factor” in medicine⁶.

The stroke incidence is nowadays declining in many developed countries as a result of Best Medical Therapy (BMT) with antihyperlipidemic (statins), antihypertensive medication and smoking reduction. The absolute number of strokes is, however, increasing, due to the aging population. Annually, fifteen million people worldwide suffer a stroke. Of this, five million die and another five million are left permanently disabled, placing a burden on family and community⁷ (Figures 2,3). The modern healthcare system cannot also overlook the high expenses that are given to deal with these disabilities.



Figures 2 and 3: World Health Organization (WHO) on deaths from stroke and global burden of stroke in 2002.



Strokes are classified based on the TOAST (*acronym for "Trial of ORG 10172 in Acute Stroke Treatment"*) classification as follows by Adams et al⁸:

- i) Cardioembolic strokes
- ii) Large vessel disease strokes
- iii) Small vessel disease strokes
- iv) Strokes of unusual causes
- v) Strokes of undetermined origin.

Of these, large vessel disease strokes account for 20-40% of all ischemic strokes. Extracranial (carotid) occlusive disease due to atheromatous disease is therefore a major causative factor for stroke, and has been thus extensively studied.

More than 60 years have passed since the legendary vascular surgeon Michael DeBakey successfully performed the first Carotid Endarterectomy (CEA) for atheromatous disease and stroke prevention in 1953, with excellent short- and long-term results as seen from his reports in 1975⁹.

Since then, an increasing number of CEAs were being performed, giving rise to the first studies for treating chronic carotid artery obstruction¹⁰. Likewise, as the operation became more well-studied, the complications of this surgical procedure came to light, with the most devastating ones being the intraoperative and postoperative stroke, the same condition the surgeon strives to protect the patient from, compromising the potential benefit of CEA.

Chapter 1.2. Carotid Endarterectomy (CEA)

Endarterectomy is one of the fundamental operations of vascular surgery. It is in essence the removal of atherosclerotic plaques that narrow the arterial lumen. CEA is one of the commonest vascular operations and it is used as a preventive rather than therapeutic measure. There have been numerous techniques described for CEA, but the two most

commonly utilized are conventional (standard) CEA and eversion CEA. Both techniques are durable with no significant differences regarding the perioperative mortality and morbidity or the recurrent stenosis, as reported in the EVEREST study¹¹.

The bloom of CEA between 1970 and 1990, however, seemed to come with a cost, as many studies reported an unacceptably high complication rate, compromising its benefit. The complications associated with CEA are the perioperative stroke or TIA, myocardial infarction (MI), cerebral hyper perfusion syndrome, cranial nerve injuries, wound infections and bleeding. Also, as a late complication, one should not forget the incidence of recurrent carotid stenosis. This particular complication is somewhat difficult to estimate and report, as the various papers on the literature report different criteria on different times regarding the follow-up. Nevertheless, it is an important complication compromising CEA's benefit.

These facts led surgeons and clinical researchers to search better preoperative, intraoperative and postoperative care and alternatives for their patients. Firstly, three large RCTs in the beginning of the '90s (NASCET, ESCT, ACAS) identified the exact subgroups of patients with carotid artery stenosis that would benefit from CEA over best medical therapy, and set the stage for the first guidelines for carotid artery occlusive disease¹²⁻¹⁴. Arteriotomy closure was studied and methods compared (primary closure, vein patching, synthetic patching)¹⁵, anesthesia type was also studied^{16,17}, as were perioperative medications (β -blockers, reverse of classic heparin with protamine sulfate, etc.)¹⁸. In the late '90s, Carotid Artery Stenting (CAS) made its appearance, as an alternative, less invasive technique for patients with carotid artery stenosis, especially for those who were older and theoretically at a greater perioperative risk. This new intervention came to light with the rise of the endovascular era. After numerous studies (CREST, SAPPHIRE, SPACE, EVA3S, CAVATAS, Kentucky Study etc.)¹⁹⁻²⁴, however, its advocates have failed to establish its superiority against CEA for all subgroups of patients. After all these years, CEA remains the gold standard to treat this patient population.

Chapter 1.3. Vascular Defects

Carotid endarterectomy is a preventive measure for patients with a high risk for stroke. Thus, the periprocedural stroke as a complication is particularly tragic. Understandably, technical perfection is paramount, perhaps more than any other procedure Vascular Surgery has upon its roof.

In 1967, Blaisdell et al examined many arterial reconstruction sites intraoperatively using digital subtraction angiography (DSA) and found that a large number of surgical operations are technically imperfect, up to 26%, with potential deadly adverse outcomes owing to this suboptimal technique²⁵. Strive for perfection led many surgeons to find a way to actively and accurately find these technical imperfections and repair them if needed, as they may be responsible for up to 60% of perioperative strokes²⁶.

Since then, many imaging modalities have been used traditionally for this purpose. The most common is DSA, but also clinical inspection and palpation, pulsed-wave Doppler, angioscopy, plethysmography and even intravascular ultrasound (IVUS) have been occasionally used²⁷⁻³⁰. However, none of these has more potential than the intraoperative use of Duplex Ultrasound (DUS), with or without color Doppler. Its pros and cons are well established both in the literature and in clinical practice, but in this era of financial instability, its cheap and repeatable, non-invasive nature make this imaging modality the perfect candidate for the intraoperative completion study of CEA, among other vascular procedures³¹⁻³³.

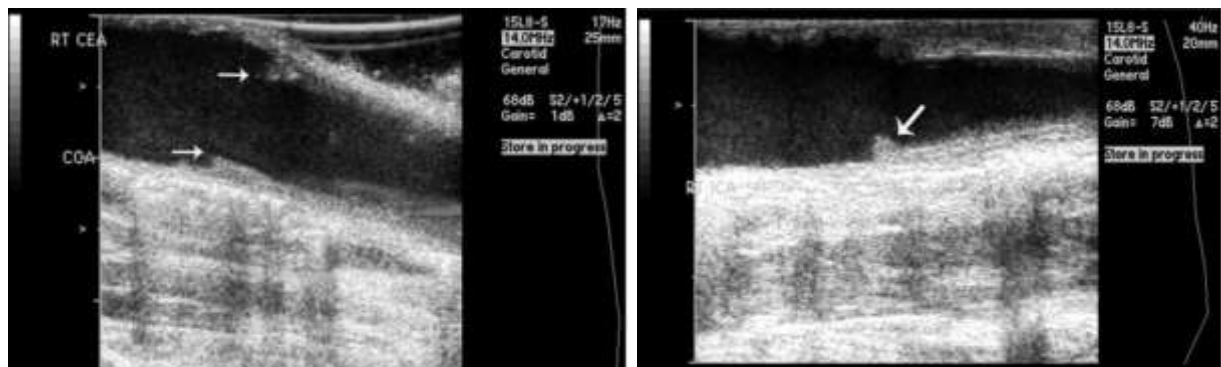
Intraoperative ultrasound has proven its usefulness during many procedures except CEA. It has been used successfully during both vascular reconstructions in other vascular

beds (femoral, popliteal, renal arteries) and non-vascular operations (hemihepatectomies, Whipple Procedure etc.)³². CEA offers a nice plane and a relatively straightforward vessel to work with and identify unsuspected technical results.

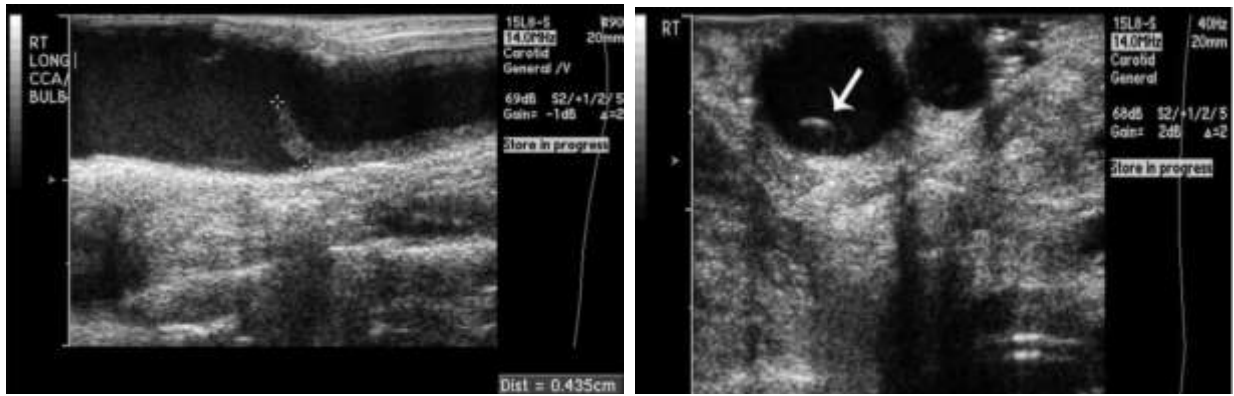
The defects that can be identified with a completion study are as follows³³:

- i) Intimal flaps
- ii) Residual plaque
- iii) Residual stenosis
- iv) Arterial kinking
- v) Arterial thrombosis
- vi) Flow turbulence

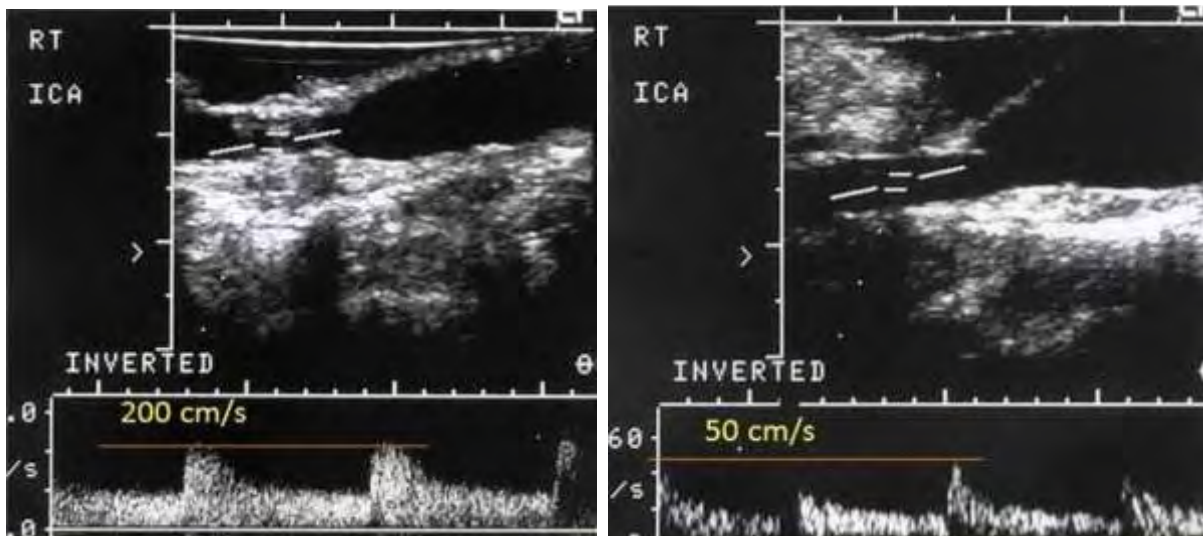
The last one is identifiable by ultrasound, manifested by elevated Peak Systolic Velocity (PSV) and can be related to an arterial spasm rather than a technical mistake. This has led some surgeons to inject the artery with a vasodilator agent (papaverine) and monitor its reaction, in order to avoid unneeded revisions⁵⁴. Intimal (dissection) flaps are the most common defects detected and are mostly found at the distal endarterectomy end, where a “shelf” between the endarterectomised and non-endarterectomised arterial segment develops. This is the reason many surgeons prefer to use “tacking” sutures at this site, as these flaps could lead to dissection and thrombosis with the blood flow at this area. Residual plaque and stenosis are caused by an incomplete endarterectomy and could lead to early recurrent stenosis, and kinking may lead to flow turbulence, low flow and thrombosis. Thrombosis, however, as an intraoperative finding, is a rare but devastating defect, that if left untreated, leads to an immediate and acute carotid obstruction resulting in a subsequent catastrophic stroke (*Figures 4-11*).



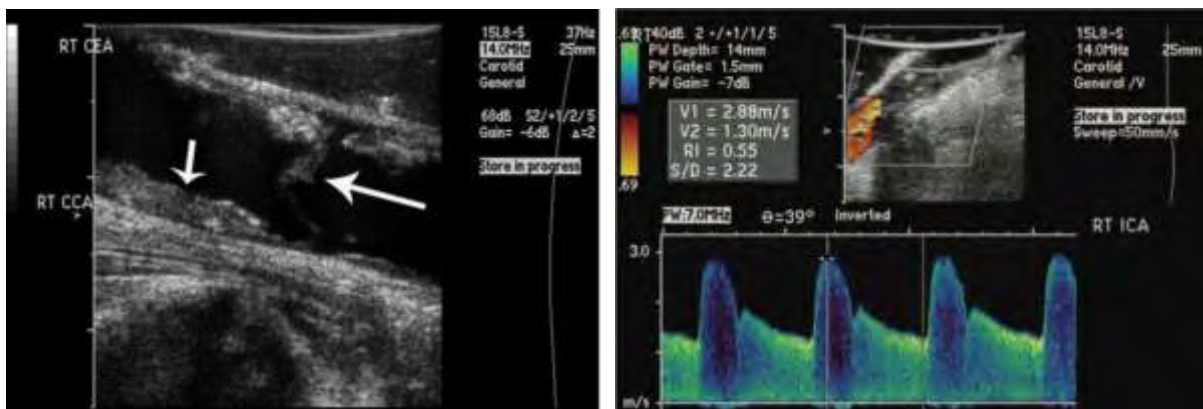
Figures 4 and 5: Left: Normal post-endarterectomy proximal site, where the “shelf” forms between the endarterectomised and the non-endarterectomised segment of the carotid artery. The proximal site needs no “tacking” sutures, as the flow of the blood does not lift up the intimal flaps. Right: small intimal flap at a post-endarterectomy distal site. Here the flow of the blood lifts the intimal flap a little, as seen in the photo. This intimal flap however is very small and likely to regress on later imaging. Here the use of “tacking” sutures by the surgeon is common for larger flaps. Photos obtained from Weinstein et al – 2015³³.



Figures 6 and 7: Large (4,35mm) intimal flap at the distal endarterectomy site, lifted by the blood current, as seen in longitudinal (left) and transverse (right) planes. This flap may lead to flow obstruction and thrombosis, and needs revision. Photos obtained from Weinstein et al – 2015³³.



Figures 8 and 9: Residual stenosis (left), as seen in the image and the PSV=200cm/sec, that was revised with a vein patch (right). The post-revision completion ultrasound shows a PSV=50cm/sec. Photos obtained from Parsa et al – 2013³².



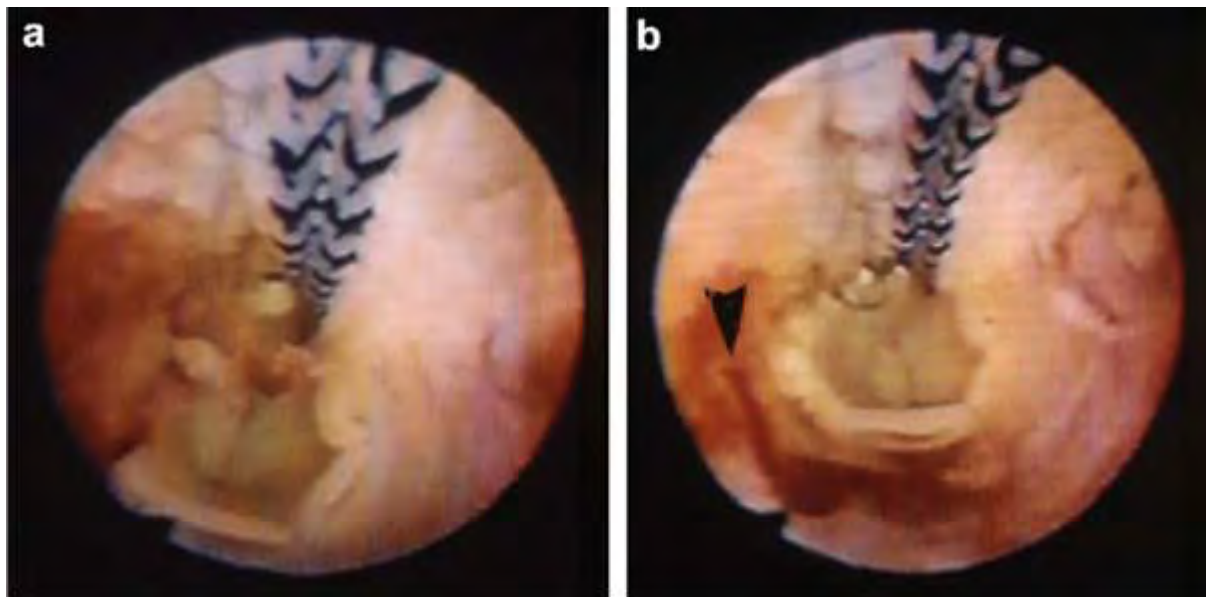
Figures 10 and 11: Substantial residual plaque (short arrow) and intimal flap (large arrow) after an endarterectomy, that probably need revision (left). When left untreated, many of these large and significant defects may lead to thrombosis (right) at the endarterectomised site, with devastating consequences. Photos obtained from Weinstein et al – 2015³³.

Chapter 1.4: Intraoperative Ultrasound

Duplex Ultrasound is an imaging modality that plays a critical role on many vascular conditions and pathologies, especially regarding carotid artery stenosis. For the patient undergoing CEA, duplex ultrasound and color-coded Doppler is the first diagnostic test performed, either for symptomatic or asymptomatic patients (screening) and, more times than not, the sole imaging study needed for intervention planning preoperatively.

Its advantages are well established in literature and in clinical practice. It offers a readily available device that every small community hospital has and is independent of expensive and specialized equipment, like the C-arm for DSA. It offers imaging without the need for iodine-based contrast agents that may compromise kidney function and bypasses the hazard of radiation exposure for both patient and surgical team. It is a repeatable, non-invasive procedure, as it needs no needle access like DSA, angiography or IVUS (*Figures 12-14*), with high accuracy and provides valuable hemodynamic information. The drawbacks are its inability to study the distal part of the ICA, especially when a high CCA bifurcation is present, and of course its operator-dependent nature. This universal disadvantage of ultrasound is of particularly profound importance, as many surgeons strive with the ultrasound learning curve, leading to consultation of another specialist to perform the study in the operating room, usually that of a vascular technologist.

Last but not least, in a healthcare world that is increasingly cost-centric, intraoperative ultrasound provides a cost-effective completion study when compared to other imaging modalities (DSA, IVUS) or to no study at all, as stated by Burnett et al in 2005³⁶.



Figures 12 and 13: Angioscopy after a carotid endarterectomy. On the right, the arrow shows a thrombus. It was re-explored and thought to have originated from a transected vasa vasorum, and then repaired. Photo obtained from Sharpe et al – 2012³⁰.

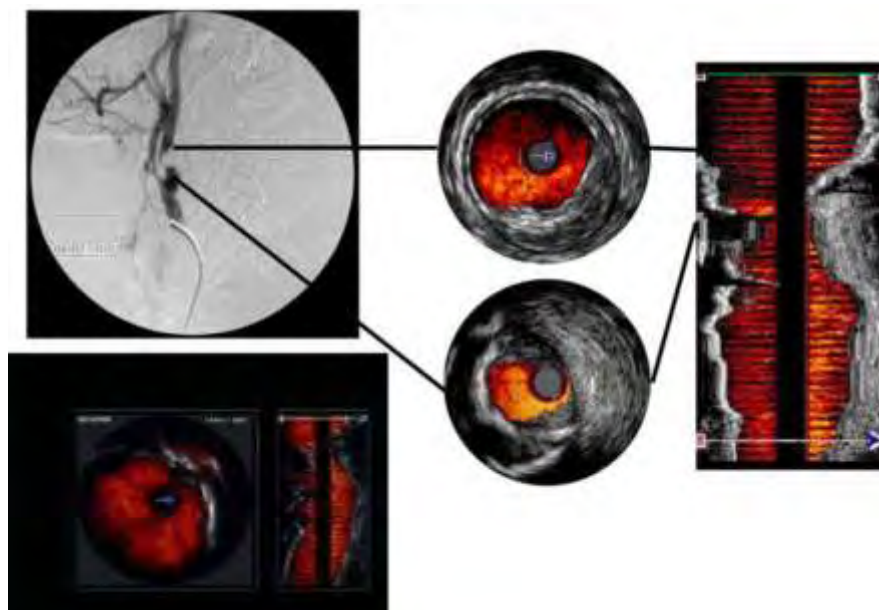


Figure 14: Intravascular ultrasound (IVUS) for imaging of a carotid artery stenosis. IVUS has been occasionally used by some surgeons as the intraoperative completion imaging modality after CEA, but has not been widely adopted, as it is expensive, difficult to use and interpret, and requires arterial puncture. It is more commonly used for evaluation of aortic dissections.

The technique of intraoperative ultrasound during CEA is relatively straightforward: after completion of the arterial reconstruction and Arteriotomy closure, and before wound closure, a probe with a frequency of 10-15MHz (min 5MHz, max 20MHz) is placed in a sterile sheath with usual ultrasound gel and the wound is filled with saline to ensure better acoustic coupling. The probe is usually shaped like a hockey-stick. The Doppler angle is retained under 60 degrees at all times. B-mode images, with or without color-Doppler are taken, peak systolic velocity (PSV) and end-diastolic velocity (EDV) are measured and the aforementioned defects identified and recorded. If there is a need for revision of the procedure, the completion study is repeated after re-intervention. Usual scanning times are about 10 minutes. Both longitudinal and transverse planes are visualized^{32,33}.

The rationale behind ultrasound completion study during CEA, except from the advantages that were mentioned earlier, is that it provides a safe, fast, easy and cheap imaging modality as a quality control method, that identifies technical imperfections and has the potential to improve postoperative outcomes (complications and residual stenosis). It also provides the much needed assurance to the surgeon that the operation was a technical success⁶⁰, and holds promise as a teaching modality for younger vascular surgeons, prompting refinement of technique, as reported by Padayachee³⁷. Furthermore, it ensures the archive of a perioperative imaging study in the same modality (DUS) that is likely used preoperatively and postoperatively, that can be used as a comparator to draw future conclusions. Pross et al even proposed that with normal intraoperative DUS, the first early postoperative ultrasound scan can be forfeited safely, and surveillance started even at one year after the operation, further noting the cost-effective nature of this intervention^{57,61,62}.



Figure 15: "Hockey stick" linear array ultrasound transducer, the most commonly used during intraoperative ultrasound after CEA.

It is therefore self-understandable, that intraoperative ultrasonic imaging is the perfect candidate for completion study after CEA, yielding potential valuable benefit for a procedure that is applied so often, but has been doubted equally often.

Chapter 2: Materials and Methods

Chapter 2.1: Inclusion Criteria

The criteria to include a paper to the analysis were set to identify all studies that use B-mode ultrasound with or without colour-Doppler as their imaging modality for completion study after CEA.

This paper is a systematic review of the literature with a meta-analysis of the results, following the methodology as reported on the PRISMA statement³⁸. The PICO-TS acronym is therefore formed as follows:

P: patients undergoing CEA. The indications for CEA were set by the operating surgeons and authors at the time of each individual study and have been well established by the NASCET and the ESCT studies.

I: intervention is the intraoperative B-mode ultrasound with or without colour-Doppler.

C: comparison was made between the results of ultrasound completion study and the results of no completion study at all. The comparator used was a meta-analysis for symptomatic and asymptomatic patients of all the RCTs regarding CEA and its complications, as well as the latest guidelines from The Society of Vascular Surgery (SVS), the American Heart Association (AHA) and the European Society for Vascular Surgery (ESVS)⁷⁷⁻⁸².

O: outcomes measured were the intraoperative findings – finding rate, the revision rate, the combined 30day myocardial infarction (MI), stroke and death rate, and the recurrent stenosis rate.

T: no time of publication or operation limit was set.

S: study type is that of a systematic review and meta-analysis of all studies (randomised, quasi-randomised or non-randomised) that meet the inclusion criteria.

Further inclusion criteria were: English language (all non-English papers were excluded) and full access to the study (when only the abstract of the article was available, the study was excluded).

Chapter 2.2: Search Strategy

Between May 2018 and May 2019, a systematic research of the literature was performed online. An algorithm was used to approach the search as follows:

((*carotid AND endarterectomy*) OR (*carotid AND reconstruction*) OR (*carotid AND stenosis*) OR (*vascular AND defects*) AND (*intraoperative*) OR (*intraoperative AND assessment*) OR (*intraoperative AND duplex AND ultrasonography*) OR (*intra-operative AND duplex*) OR (*intraoperative AND duplex AND scanning*) OR (*intra-operative AND colour AND duplex*) OR (*operative AND ultrasonography*) OR (*intraoperative AND ultrasonography*) OR (*intraoperative AND colour-flow AND duplex*) OR (*intraoperative AND duplex AND scan*)),

for titles, abstracts and keywords as published in the literature. No MeSH terms were used.

The databases searched were:

- i) MEDLINE / PubMed
- ii) Scopus
- iii) Cochrane Library for Systematic Reviews
- iv) Cinahl
- v) Ebsco
- vi) LILACS
- vii) Grey Literature
- viii) Clinicaltrials.gov

Unfortunately, no access to the Embase database was achieved via the uth or auth library.

In the Cochrane, Cinahl, Ebsco, LILACS, Grey Literature and clinicaltrials.gov, no results were found using this algorithm, so broader free-text terms like “carotid endarterectomy” and “intraoperative ultrasound” were used. No results were relevant. No ongoing trials exist. In MEDLINE / PubMed and Scopus, the algorithm produced the results used in this study, as noted by the following flow-charts.

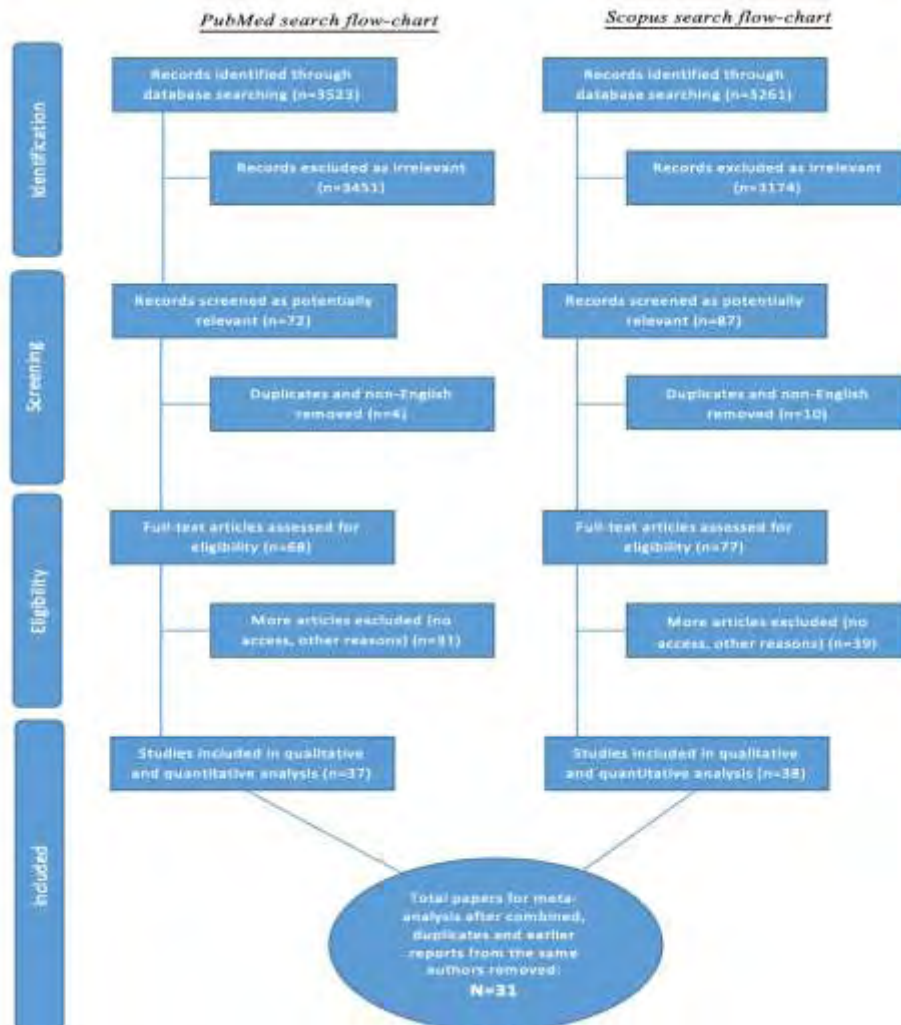


Figure 4: Combined flow-chart for PubMed and Scopus.

Chapter 3: Results

Chapter 3.1: General Results

The search identified a final 31 studies, none of which is an RCT, all are in English and all are obtained with full access³⁹⁻⁶⁹. The earliest paper about the topic reported was on 1983³⁹ and the latest on 2014⁶⁹, spanning a total of 32 years, without having a clear conclusion on the intraoperative use of the ultrasound. The total patient number is 4800 and the number of CEAs performed is 5097, as some patients underwent bilateral operations. One study with 47 operations reported (Pross et al – 2001⁶¹) was further excluded, as it did not report the number of the findings, revisions or complications, leaving 5050 CEAs.

All available information was tabled, including patient number, age, sex, operation number, finding number, finding rate, finding location, revision number and revision rate, revision cut-off, subtype of CEA, U/S type and probe used, type of anaesthesia, time of study in minutes, number of combined 30day death, stroke and MI and 30day mortality and morbidity rate from these, as also recurrent stenosis rate.

The endpoints analysed were:

1. Finding rate.
2. Revision rate.
3. 30day stroke, death and MI (myocardial infarction) combined rate.
4. Recurrent stenosis rate.

The program used for statistic analysis of the data was the MedCalc Statistical Software, version 19.0.5 (*MedCalc Software bvba, Ostend, Belgium; <https://www.medcalc.org>: 2019*).

Table 1. List of publications using intraoperative Duplex Ultrasound with or without colour-Doppler as the imaging modality for a completion study after Carotid Endarterectomy (CEA).

Investigators	Number of patients	Number of CEAs performed	Number of findings (%)	Number of revisions (%)
<i>Sigel et al¹ - 1983</i>	73	73	20 (27,9%)	3 (4,1%)
<i>*Zierler et al² - 1984</i>	50	50	7 (14%)	2 (4%)
<i>Selfert et al³ - 1985</i>	218	229	30 (13,1%)	22 (9,6%)
<i>Ackroyd et al⁴ - 1985</i>	155	155	36 (23,2%)	7 (4,5%)
<i>Dilley et al⁵ - 1986</i>	145	145	52 (35,9%)	26 (17,9%)
<i>*Lane et al⁶ - 1987</i>	175	175	33 (18,9%)	12 (6,9%)
<i>Schwartz et al⁷ - 1988</i>	76	84	17 (20%)	8 (9,5%)
<i>Sawchuk et al⁸ - 1989</i>	80	80	21 (26,3%)	0 (0%)
<i>Kinney et al⁹ - 1993</i>	379	410	73 (17,8%)	26 (5,6%)
<i>Bandyk et al¹⁰ - 1994</i>	210	210	24 (11,4%)	17 (8,1%)
<i>Haff et al¹¹ - 1994</i>	44	44	14 (31,9%)	3 (6,8%)
<i>Lingenfelter et al¹² - 1995</i>	50	53	15 (28,3%)	6 (11,3%)
<i>Lipski et al¹³ - 1995</i>	36	39	9 (23,1%)	9 (23,1%)
<i>Papanicolaou et al¹⁴ - 1996</i>	78	86	10 (11,6%)	10 (11,6%)
<i>Gaunt et al¹⁵ - 1996</i>	100	100	36 (36%)	2 (2%)
<i>Dorffner et al¹⁶ - 1997</i>	50	50	19 (38%)	9 (18%)
<i>Steinmetz et al¹⁷ - 1998</i>	95	100	13 (13%)	2 (2%)
<i>Roth et al¹⁸ - 1999</i>	221	242	34 (14%)	12 (5%)
<i>*Mansour et al¹⁹ - 1999</i>	560	621	166 (26,7%)	20 (3,2%)
<i>*Walker et al²⁰ - 1999</i>	120	120	24 (20%)	9 (7,5%)
<i>Seelig et al²¹ - 1999</i>	102	115	29 (25,2%)	14 (12,2%)
<i>Mays et al²² - 2000</i>	96	100	33 (33%)	16 (16%)
<i>Prass et al²³ - 2001</i>	47	47	NR	NR
<i>Krug et al²⁴ - 2001</i>	78	78	6 (7,7%)	1 (1,3%)
<i>Panneton et al²⁵ - 2001</i>	149	155	64 (41,3%)	14 (9%)
<i>*Padayachee et al²⁶ - 2002</i>	244	244	68 (27,9%)	9 (3,7%)
<i>Mullenix et al²⁷ - 2003</i>	100	100	34 (34%)	7 (7%)
<i>Valenti et al²⁸ - 2003</i>	138	141	36 (25,5%)	4 (2,8%)
<i>*Ascher et al²⁹ - 2004</i>	590	650	42 (6,5%)	15 (2,3%)
<i>Winkler et al³⁰ - 2007</i>	116	116	21 (18,1%)	1 (0,8%)
<i>Yuan et al³¹ - 2014</i>	225	285	27 (9,5%)	11 (3,9%)
Totals:	4800	5097	1013 (20%)	297 (5,88%)

*These studies contain older studies from the same institutions and/or authors, that are included in the latter publication. Specifically, Zierler et al contains a study of the previous year from the same author⁷⁰, Lane et al contains a study from the same author five years before this one⁷¹, Mansour et al contains a study from the same institution five years ago⁷², Walker et al contains a study from the same author five years ago⁷³, Padayachee et al contains two studies from the same author four and three years ago^{74,75}, and Ascher et al contains a study from the same author two years ago⁷⁶. These former studies were of course excluded from the meta-analysis, as their results are contained on the latter publications.

Chapter 3.2: Endpoint 1 – Finding rate

Q	312,4859
DF	29
Significance level	P < 0,0001

In order to estimate the mean abnormal finding rate of all available studies, a heterogeneity test was made between them and the Q and I² tests were run.

I ² (inconsistency)	90,72%
95% CI for I ²	87,88 - 92,89

From the following table it is concluded that a significant statistical heterogeneity exists (p<0,0001) and that the I² factor exceeds 90%.

For this reason, and to estimate best the pooled results, the random effects estimation model was used. The results were as follows (*Table 2*):

Study	Sample size	Proportion (%)	95% CI	Weight (%)
				Random
Sigel et al - 1983	73	27,397	17,606 - 39,094	3,14
Zierler et al - 1984	50	14,000	5,819 - 26,740	2,89
Seifert et al - 1985	229	13,100	9,016 - 18,171	3,59
Ackroyd et al - 1985	155	23,226	16,828 - 30,676	3,47
Dilley et al - 1986	145	35,862	28,075 - 44,240	3,45
Lane et al - 1987	175	18,857	13,350 - 25,450	3,51
Schwartz et al - 1988	84	20,238	12,254 - 30,414	3,21
Sawchuk et al - 1989	80	26,250	17,041 - 37,285	3,19
Kinney et al - 1993	410	17,805	14,224 - 21,858	3,70
Bandyk et al - 1994	210	11,429	7,461 - 16,526	3,56
Hoff et al - 1994	44	31,818	18,610 - 47,578	2,80
Lingenfelter et al - 1995	53	28,302	16,786 - 42,348	2,93
Lipski et al - 1995	39	23,077	11,134 - 39,326	2,71
Papanicolaou et al - 1996	86	11,628	5,719 - 20,346	3,22
Gaunt et al - 1996	100	36,000	26,641 - 46,212	3,30
Dorffner et al - 1997	50	38,000	24,650 - 52,825	2,89
Steinmetz et al - 1998	100	13,000	7,107 - 21,204	3,30
Roth et al - 1999	242	14,050	9,930 - 19,076	3,60
Mansour et al - 1999	621	26,731	23,287 - 30,398	3,75
Walker et al - 1999	120	20,000	13,255 - 28,281	3,38
Seelig et al - 1999	115	25,217	17,584 - 34,169	3,36
Mays et al - 2000	100	33,000	23,920 - 43,117	3,30
Krug et al - 2001	78	7,692	2,875 - 15,995	3,17
Panneton et al - 2001	155	41,290	33,452 - 49,469	3,47
Padayachee et al - 2002	244	27,869	22,338 - 33,946	3,60
Mullenix et al - 2003	100	34,000	24,822 - 44,153	3,30
Valenti et al - 2003	141	25,532	18,567 - 33,554	3,44
Ascher et al - 2004	650	6,462	4,696 - 8,634	3,75
Winkler et al - 2007	116	18,103	11,570 - 26,332	3,36
Yuan et al - 2014	285	9,474	6,336 - 13,484	3,64
- tal (random effects)	5050	21,885	18,142 - 25,875	100,00

Table 2. Random effects estimation for abnormal finding rate.

It is concluded that every study has similar weight and that no specific study has a bigger effect on the final result. The mean finding rate is 21,9% (18,1-25,9, 95% CI).

A funnel plot was conducted to determine whether a publication bias exists (*Figure 16*). As it is shown, almost every study is inside the cone, except for two, which are however

on different sides of the plot, giving further credit and proving no existing publication bias. A forest plot is further provided for this endpoint (*Figure 17*).

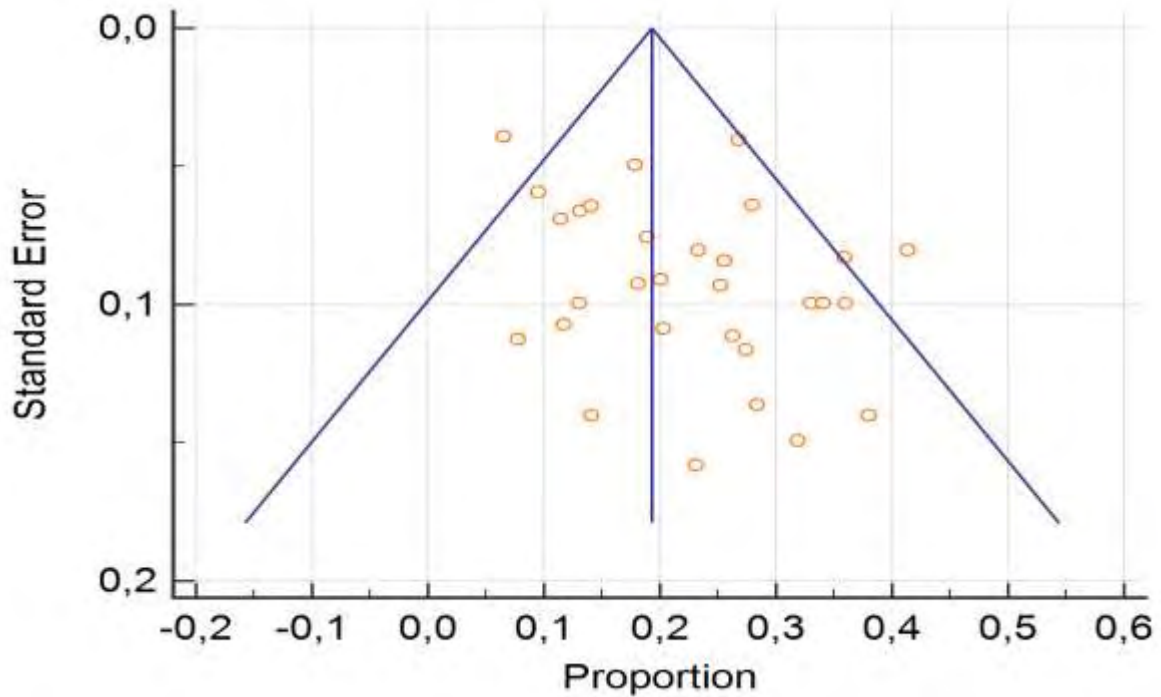


Figure 16: Funnel plot for the finding rate endpoint.

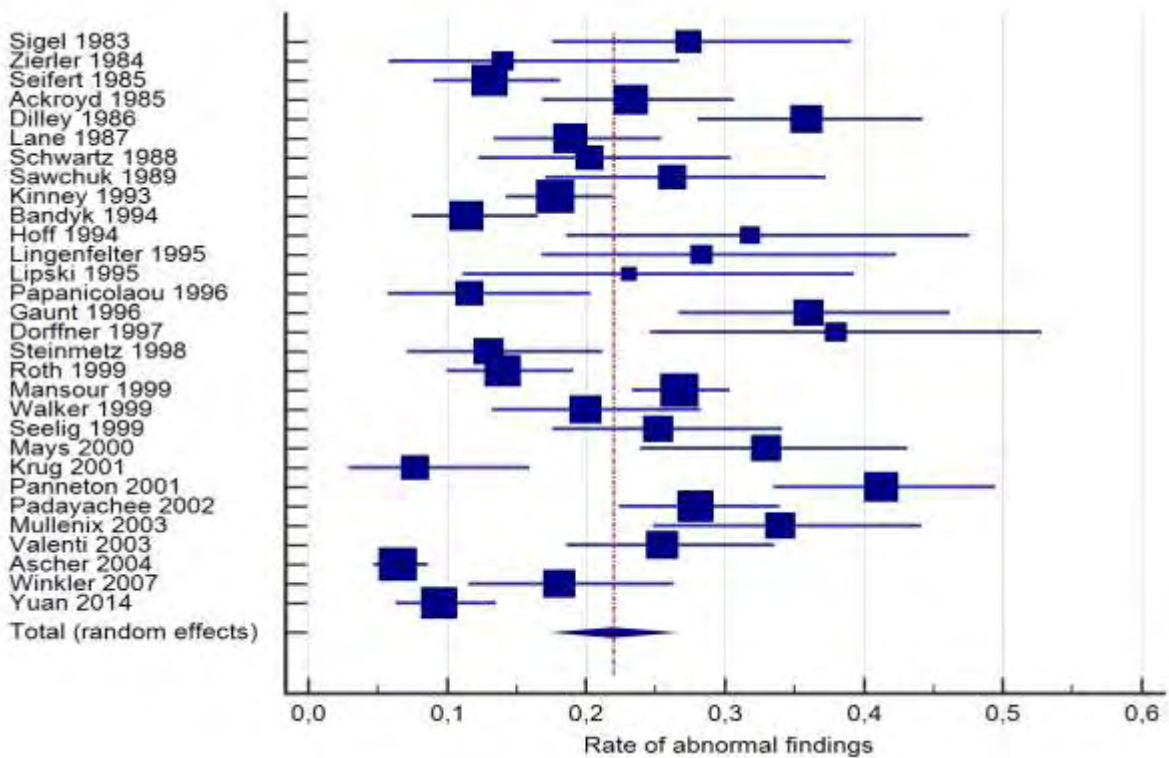


Figure 17: Forest plot for the finding rate endpoint.

Chapter 3.3: Endpoint 2 – Revision rate

Again, a heterogeneity test for the revision rate endpoint was run, showing the statistically significant heterogeneity ($p < 0,0001$), with the I^2 factor over 80%. The same random effects estimation model is used (Table 3).

Q	146,9854
DF	29
Significance level	P < 0,0001
I^2 (inconsistency)	80,27%
95% CI for I^2	72,51 - 85,84

Study	Sample size	Proportion (%)	95% CI	Weight (%)
				Random
Sigel et al - 1983	73	4,110	0,856 - 11,544	2,92
Zierler et al - 1984	50	4,000	0,488 - 13,714	2,51
Seifert et al - 1985	229	9,607	6,119 - 14,184	3,84
Ackroyd et al - 1985	155	4,516	1,835 - 9,083	3,58
Dilley et al - 1986	145	17,931	12,060 - 25,159	3,53
Lane et al - 1987	175	6,857	3,593 - 11,672	3,67
Schwartz et al - 1988	84	9,524	4,202 - 17,906	3,06
Sawchuk et al - 1989	80	0,000	0,000 - 4,506	3,01
Kinney et al - 1993	410	6,341	4,184 - 9,154	4,11
Bandyk et al - 1994	210	8,095	4,786 - 12,645	3,79
Hoff et al - 1994	44	6,818	1,429 - 18,656	2,37
Lingenfelter et al - 1995	53	11,321	4,270 - 23,029	2,58
Lipski et al - 1995	39	23,077	11,134 - 39,326	2,24
Papanicolaou et al - 1996	86	11,628	5,719 - 20,346	3,08
Gaunt et al - 1996	100	2,000	0,243 - 7,038	3,22
Dorffner et al - 1997	50	18,000	8,576 - 31,437	2,51
Steinmetz et al - 1998	100	2,000	0,243 - 7,038	3,22
Roth et al - 1999	242	4,959	2,588 - 8,502	3,87
Mansour et al - 1999	621	3,221	1,978 - 4,930	4,24
Walker et al - 1999	120	7,500	3,487 - 13,760	3,38
Seelig et al - 1999	115	12,174	6,818 - 19,582	3,34
Mays et al - 2000	100	16,000	9,431 - 24,679	3,22
Krug et al - 2001	78	1,282	0,0325 - 6,937	2,98
Panneton et al - 2001	155	9,032	5,026 - 14,690	3,58
Padayachee et al - 2002	244	3,689	1,700 - 6,886	3,87
Mullenix et al - 2003	100	7,000	2,861 - 13,892	3,22
Valenti et al - 2003	141	2,837	0,778 - 7,104	3,51
Ascher et al - 2004	650	2,308	1,297 - 3,778	4,25
Winkler et al - 2007	116	0,862	0,0218 - 4,710	3,35
Yuan et al - 2014	285	3,860	1,942 - 6,801	3,95
- tal (random effects)	5050	6,513	4,993 - 8,219	100,00

Table 3. Random effects estimation for revision rate.

It is concluded that every study has similar weight and that no specific study has a bigger effect on the final result. The mean revision rate is 6,5% (5-8,2, 95% CI).

The funnel plot shows also no publication bias on this endpoint. The relevant forest plot is provided (Figures 18 and 19).

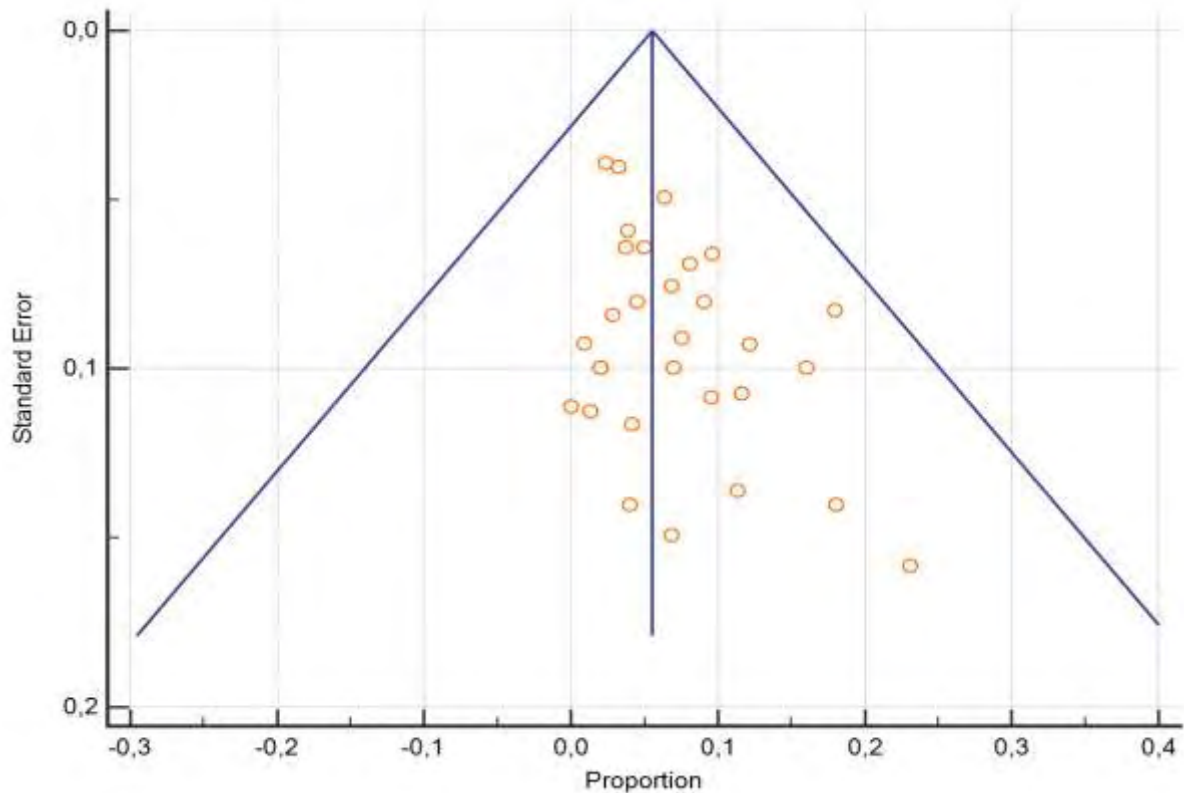


Figure 18: Funnel plot for the revision rate endpoint.

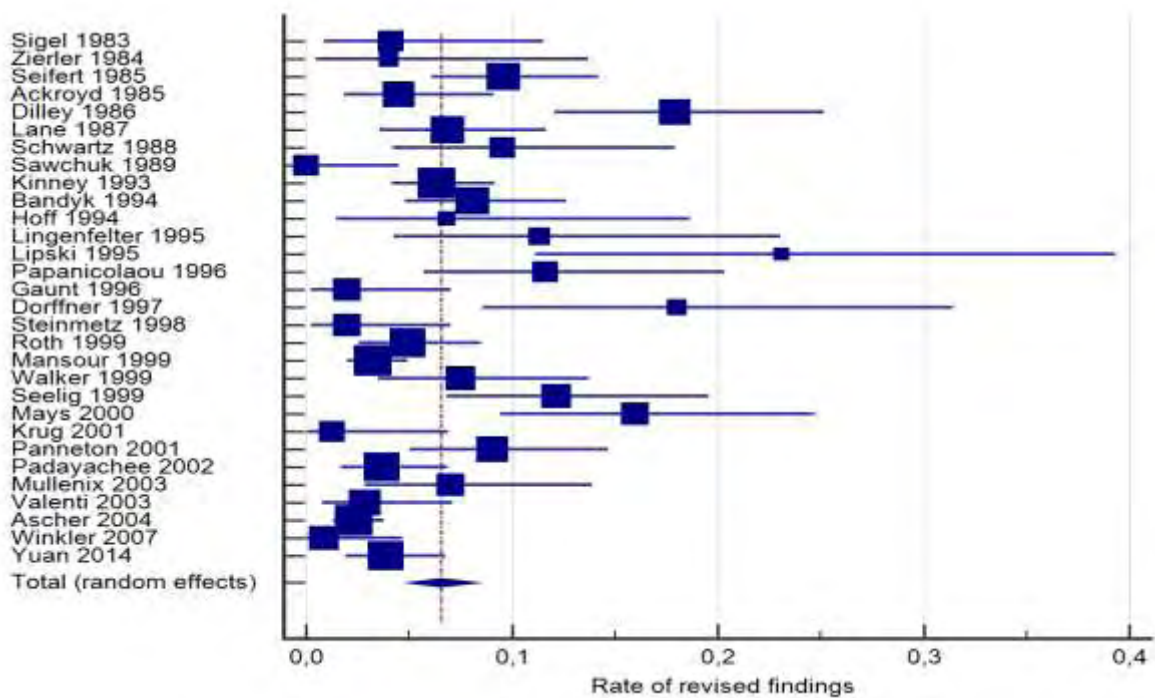


Figure 19: Forest plot for the revision rate endpoint.

Chapter 3.4: Endpoint 3 – 30day stroke, death and MI combined rate

The combined 30day stroke, death and MI rate is analyzed. Again, the heterogeneity test shows a statistically significant heterogeneity ($p < 0,0001$) with a I^2 factor exceeding 75%. The random effects estimation model is used (Table 4).

Q	106,6724
DF	26
Significance level	P < 0,0001
I^2 (inconsistency)	75,63%
95% CI for I^2	64,69 - 83,18

Study	Sample size	Proportion (%)	95% CI	Weight (%)
				Random
Zierler et al - 1984	50	0,000	0,000 - 7,112	2,61
Ackroyd et al - 1985	155	5,161	2,254 - 9,916	4,00
Dilley et al - 1986	145	0,690	0,0175 - 3,782	3,94
Lane et al - 1987	175	2,286	0,626 - 5,749	4,13
Schwartz et al - 1988	84	4,762	1,313 - 11,746	3,29
Sawchuk et al - 1989	80	5,000	1,379 - 12,310	3,23
Kinney et al - 1993	410	7,561	5,195 - 10,561	4,77
Bandyk et al 1994	210	0,000	0,000 - 1,741	4,29
Hoff et al - 1994	44	13,636	5,173 - 27,351	2,45
Lingenfelter et al - 1995	53	5,660	1,183 - 15,663	2,69
Lipski et al - 1995	39	2,564	0,0649 - 13,476	2,29
Papanicolaou et al - 1996	86	2,326	0,283 - 8,149	3,32
Gaunt et al -1996	100	6,000	2,233 - 12,603	3,51
Dorffner et al - 1997	50	4,000	0,488 - 13,714	2,61
Steinmetz et al - 1998	100	3,000	0,623 - 8,518	3,51
Roth et al - 1999	242	0,413	0,0105 - 2,281	4,41
Mansour et al - 1999	621	0,966	0,355 - 2,091	4,97
Walker et al - 1999	120	0,000	0,000 - 3,027	3,73
Seelig et al - 1999	115	3,478	0,956 - 8,667	3,68
Mays et al - 2000	100	3,000	0,623 - 8,518	3,51
Panneton et al - 2001	155	2,581	0,708 - 6,475	4,00
Padayachee et al - 2002	244	3,279	1,426 - 6,358	4,42
Mullenix et al - 2003	100	2,000	0,243 - 7,038	3,51
Valenti et al - 2003	141	0,709	0,0180 - 3,888	3,91
Ascher et al - 2004	650	0,769	0,250 - 1,786	4,98
Winkler et al - 2007	116	0,000	0,000 - 3,130	3,69
Yuan et al - 2014	285	1,053	0,218 - 3,045	4,54
- tal (random effects)	4670	2,531	1,652 - 3,591	100,00

Table 4. Random effects estimation for the 30day stroke, death and MI combined rate.

It is concluded that every study has similar weight and that no specific study has a bigger effect on the final result. The mean 30day stroke, death and MI combined rate is 2,53% (1,65-3,59, 95% CI), without differentiating between symptomatic and asymptomatic patients.

The funnel plot shows also no publication bias, with a remarkable homogeneity and almost no scattering beneath the cone. The relevant forest plot is also provided (Figures 20 and 21).

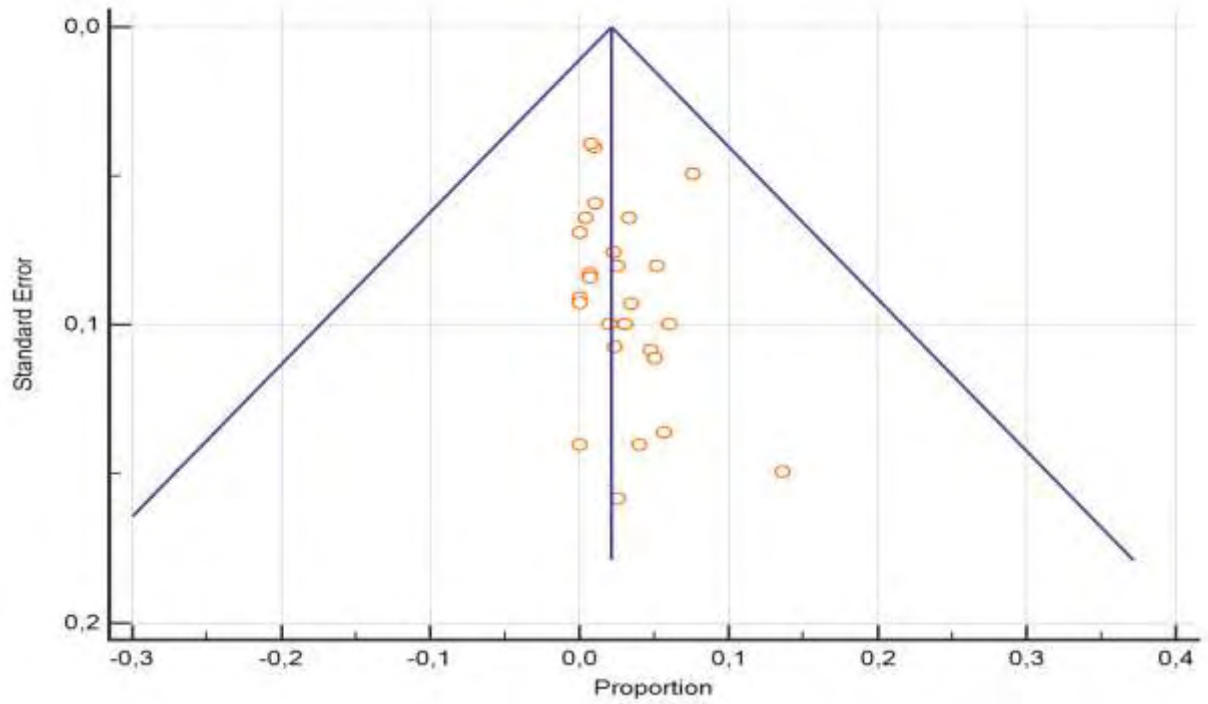


Figure 20: Funnel plot for the 30day death, stroke and MI combined rate.

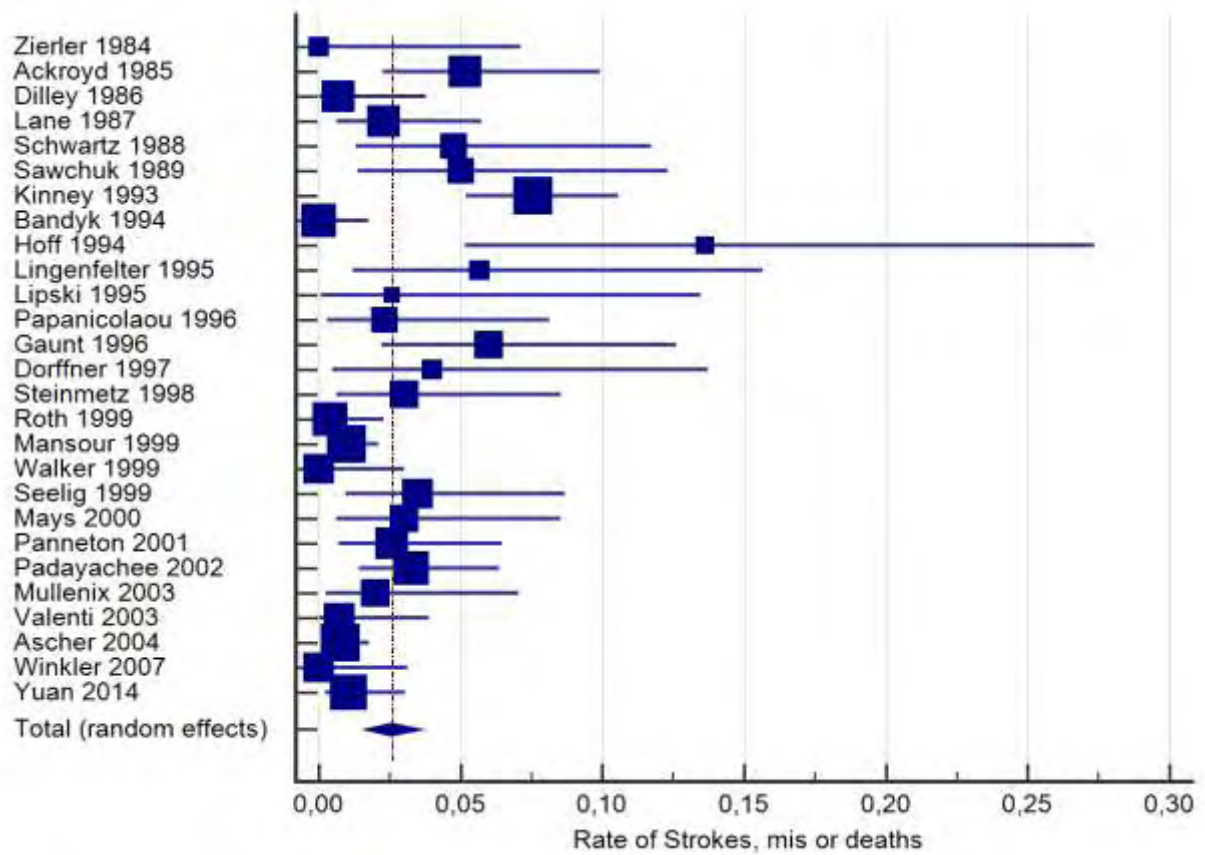


Figure 21: Forest plot for the 30day death, stroke and MI combined rate.

Chapter 3.5: Endpoint 4 – Recurrent stenosis rate

Recurrent stenosis as an endpoint is difficult to conclude, as the authors use different times and different values of stenosis percentage to report it. It was concluded that it would be methodologically unsound to analyze the data with conventional statistical means and it would produce wrong conclusions. The impression left by studying the data is that small defects do not alter the natural history of recurrent stenosis, as it is a condition thought to be caused by intimal hyperplasia, but larger effects that are not revised may lead to higher recurrent stenosis rates postoperatively.

Chapter 3.6: Other results

From the pooled analysis table, some other parameters were reported, that were not further analysed as they were either inconsistently reported or transcend the purpose of this study, which is to evaluate the impact of the intraoperative ultrasound on the outcome of CEA.

Demographics from the final pooled sample were the same with these concerning patients who need to undergo CEA.

The indication for intervention was mostly reported (symptomatic vs asymptomatic patients), but none of these case series differentiated the results based on the indication and the total findings, revisions and complications were reported in total.

The location of the intraoperative finding was also mostly reported. Most abnormal findings involved the proximal ICA or the distal CCA, which are the main sites of the endarterectomy, and consisted mainly of intimal flaps without need for revision. Depending on the surgeon, others evaluated the external carotid artery (ECA) and others not. When evaluated, the ECA had a higher finding rate (either residual plaque or thrombosis), but a lower revision rate, as the management of the ECA during CEA is still under debate between vascular surgeons.

The technique used (standard vs eversion CEA) was not always reported, but the technique used on more than 90% of occasions was the standard, conventional carotid endarterectomy, thus it was not further analyzed. The impression left is that the technique type did not alter the results, but may affect the technique needed to evaluate the site with the ultrasound probe.

Different ultrasound modalities were mainly B-mode and Triplex, with the latter frequency increasing with time, as technology evolved and access to better machines was more widely acquired. The probes used were between 5 and 20 MHz, but most series reported the use of either a 7,5 or a 10MHz probe. The results however did not change with the course of time. One explanation could be that the CEA surgical technique was refined over time, but so was the imaging quality, balancing the total finding and revisions.

Finally, anesthesia type reported was mostly general, with few cases using locoregional anesthetic techniques, and thus cannot be further evaluated.

Chapter 4: Discussion

The total abnormal finding rate is 21,89%. This means that more than one out of five CEAs are technically imperfect, after more than half a century of practicing the technique, and about a third of these findings warrant re-intervention, as the revision rate was 6,51% of all CEAs. Similar rates are reported in the literature with DSA as the imaging modality of the completion study, indicating that ultrasound and angiography are at least on par with each other, regarding their finding rates. Of course, however, ultrasound has the advantages mentioned on Chapter 1. The war against error is still at large, showing the continuous need for technique refinement and alertness from the surgeon.

For this revision rate, every surgeon used his own cut-off value. When reported, these values were tabled. The most common finding rate was an intimal flap and the cut-off value for revision used most was the $PSV > 125 \text{ cm/sec}$ and the stenosis rate $> 50\%$, terms that correlate with the carotid artery diameter and are also considered “significant” preoperatively, by the Washington classification⁸³. Of course, findings like intraluminal thrombus and no flow were also revised universally.

Unfortunately, in the extensive literature searched, and even with different imaging modalities, the characterization of the defects as major and thus requiring re-intervention, or minor, is left to the discretion of the operating surgeon⁶⁵. As such, there is no consensus on the criteria on re-exploration, although Weinstein et al on their review proposed the $> 3 \text{ mm}$ intimal flap and $PSV > 125 \text{ cm/sec}$ as the cut-off for revision³³. A quantitative analysis is required to balance the benefit of re-intervention and the dangers of arterial re-clamping and longer operating times, depending on the intraoperative findings.

Naturally, potentially threatening large defects will be revised by the surgeon intraoperatively, regardless of the individual cut-off set. Minor defects, however, remain mostly unrevised. Many authors have reported on these defects’ natural history through time and their potential contribution to early recurrent stenosis, without clear results^{34,35,46,72}. They seem to mostly regress postoperatively, however their more accurate fate remains to be determined by larger studies^{44,46}. This is yet another indication of the intraoperative ultrasound’s usefulness, serving both as a measure and a surveillance imaging modality.

The 30day death, disabling stroke and MI combined rate was 2,53%, without differentiating between symptomatic and asymptomatic patients. This is a respectable reduction from the 7% for symptomatic and 3% for asymptomatic patients, rates that are deemed acceptable from recent meta-analyses about CEA, and are currently the acceptable plateaus for CEA as reported in the latest SVS and ESVS guidelines, but this reduction did not reach statistical significance ($p < 0,05$). These 7% and 3% rates are even reported without calculating the MI rate, which accounts for 0,3% of all severe complications. Excluding the MIs, the intraoperative use of ultrasound as a completion study has provided a 2% risk of disabling stroke or death postoperatively⁸⁰⁻⁸².

Recurrent stenosis is a common late complication after CEA, but it is much more common when carotid artery stenosis is treated with CAS. Unfortunately, the disparity with which the results are reported traditionally prevents safe conclusions from being made. In fact, the variety of cut-off values is so much that no more than three studies used the same criteria for reporting this recurrent stenosis in this systematic review. The individual authors’ impression is mostly that recurrent stenosis does not appear to be affected by the completion imaging, either with ultrasound or other imaging modalities. The main factor resulting in recurrent stenosis is nowadays widely accepted to be intimal hyperplasia rather than residual plaque from the endarterectomy. Other studies and therapies target this situation, that exceed the purpose of this review.

Chapter 5: Conclusions

This study tries to analyze the results of the intraoperative usage of the ultrasound as a completion study during CEA and compare the results with the ones of general and standard practice, i.e. without completion study. The total pooled patient sample is not small, it consists however of individually small, mostly retrospective and not comparative studies, with reporting loopholes, biases and large heterogeneity. Therefore, a safe conclusion cannot be made of these statistics and results.

The impression this study leaves, however, is that the ultrasound could change for the better the results of carotid endarterectomy. This is backed up by both the analysis and the complication rate of the pooled sample, and the individual impression of the authors of each study. In 28 of the 31 papers, the authors state in their conclusions that intraoperative ultrasound seems to provide better results to CEAs.

This does not mean that there are only aficionados of the routine usage of ultrasound completion studies. In a recent extensive review of all completion studies after CEA by Wallaert et al (although ultrasound was rarely exploited), they found no improvement whatsoever in their early postoperative results, only a small significant lower 1-year restenosis rate, and higher rather than lower complication rates for those cases that were revised⁸⁴. Halm et al reported on their retrospective review that intraoperative ultrasound usage was associated with a slightly larger, non-significant stroke and death rate⁸⁵.

Issue 5 on May 2013 of the Journal of Vascular Surgery hosts a nice head-to-head comparison of completion study vs no completion study, with sound arguments on both sides^{86,87}.

Setting the quantitative results (complications and restenosis rates) aside, there also seems to be a qualitative advantage of the ultrasound completion study following CEA. It provides the surgeon the safety and knowledge of a technically sound operation⁶⁰, promotes refinement of technique and is helpful teaching younger vascular surgeons³⁷, and seems to be cost-effective, both against other intraoperative imaging modalities and against no imaging at all³⁶. It also provides a measure for future references, as it is essentially the same imaging modality used both for preoperative diagnosis and evaluation and postoperative follow-up surveillance. This avoids the implication of double standards, and could safely avoid the first follow-up ultrasound, if it was intraoperatively normal.

Nevertheless, the issue needs more rigorous evidence and of course a well designed, randomized controlled trial (RCT), comparing the intraoperative use of the ultrasound with other imaging modalities or no imaging, with extensive, long-term follow-up. It is for sure a very interesting intervention and the results of this study warrant further research.

Chapter 6: Reference List

- [1]. **Osler, W.** "The principles and practice of medicine". New York: D Appleton and Co; 1892.
- [2]. **Gowers, W.R.** "On a case of simultaneous embolism of central retinal and middle cerebral arteries". *Lancet*. 1875;ii:794.
- [3]. **Chiari, H.** "Über Verhalten des Teilungswinkels der Carotis communis bei der Endarteritis chronica deformans". *Verh Dtsch Pathol Ges.* 1905;9:326–330.
- [4]. **Miller Fischer, C.** "Occlusion of the internal carotid artery". *AMA Arch Neurol Psychiatry*. 1951;65(3):346.
- [5]. **Miller Fischer, C.** "Occlusion of the Carotid Arteries - Further Experiences". *AMA Arch Neurol Psychiatry*. 1954;72(2):187-204.
- [6]. **Dawber, T.R., Meadors, G.F., Moore, F.E.Jr.** "Epidemiological Approaches to Heart Disease: The Framingham Study". Presented at a Joint Session of the Epidemiology, Health Officers, Medical Care, and Statistics Sections of the American Public Health Association, at the Seventy-eighth Annual Meeting in St. Louis, Mo., November 3, 1950.
- [7]. **World Health Organization.** "The World Health Report: 2002: Reducing risks, promoting healthy life. 2002." World Health Organization.
- [8]. **Adams, H.P., Bendixen, B.H., Kappelle, L.J., Biller, J., Love, B.B., Gordon, D.L., Marsh, E.E.** "Classification of subtype of acute ischemic stroke. Definitions for use in a multicenter clinical trial. TOAST. Trial of Org 10172 in Acute Stroke Treatment". *Stroke*. 1993 24:35-41.
- [9]. **DeBakey, M.E.** "Successful carotid endarterectomy for cerebrovascular insufficiency. Nineteen-year follow-up". *JAMA*. 1975 Sep 8;233(10):1083-5.
- [10]. **Thompson, J.E., Austin, D.J., Patman, R.D.** "Endarterectomy of the Totally Occluded Carotid Artery for Stroke: Results in 100 Operations". *Arch Surg*. 1967;95(5):791–801.
- [11]. **Cao, P., Giordano, G., De Rango, P. et al. and Collaborators of the EVEREST Study Group.** "A randomized study on eversion versus standard carotid endarterectomy. Study design and pre-liminary results. The EVEREST trial". *J Vasc Surg* 1998; 27: 595-605.
- [12]. **Ferguson, G.G., Eliasziw, M., Barr, H.W., Clagett, G.P., Barnes, R.W., Wallace, M.C., Taylor, D.W., Haynes, R.B., Finan, J.W., Hachinski, V.C., Barnett, H.J.** "The North American Symptomatic Carotid Endarterectomy Trial (NASCET): surgical results in 1415 patients". *Stroke*. 1999 Sep;30(9):1751-8.
- [13]. **Randomised trial of endarterectomy for recently symptomatic carotid stenosis: final results of the MRC European Carotid Surgery Trial (ECST).** *Lancet*. 1998 May 9;351(9113):1379-87.
- [14]. **Endarterectomy for asymptomatic carotid artery stenosis. Executive Committee for the Asymptomatic Carotid Atherosclerosis Study (ACAS study).** *JAMA*. 1995 May 10;273(18):1421-8.
- [15]. **Hertzer, N.R., Beven, E.G., O'Hara, P.J., Krajewski, L.P.** "A prospective study of vein patch angioplasty during carotid endarterectomy. Three-year results for 801 patients and 917 operations". *Ann Surg*. 1987 Nov;206(5):628-35.
- [16]. **Tangkanakul, C., Counsell, C.E., Warlow, C.P.** "Local versus general anaesthesia in carotid endarterectomy: a systematic review of the evidence". *Eur J Vasc Endovasc Surg*. 1997 May;13(5):491-9.
- [17]. **Allen, B.T., Anderson, C.B., Rubin, B.G., Thompson, R.W., Flye, M.W., Young-Beyer, P., Frisella, P., Sicard, G.A.** "The influence of anesthetic technique on perioperative complications after carotid endarterectomy". *J Vasc Surg*. 1994 May;19(5):834-42;discussion 842-3.
- [18]. **Knappich, C., Kuehnl, A., Tsantilas, P., Schmid, S., Breitkreuz, T., Kallmayer, M., Zimmemann, A., Eckstein, H.H.** "Intraoperative Completion Studies, Local Anesthesia, and Antiplatelet Medication Are Associated With Lower Risk in Carotid Endarterectomy". *Stroke*. 2017 Apr;48(4):955-962.
- [19]. **Brott, T.G., Hobson, R.W. 2nd., Howard, G., Roubin, G.S., Clark, W.M., Brooks, W., Mackey, A., Hill, M.D., Leimgruber, P.P., Sheffet, A.J., Howard, V.J., Moore, W.S., Voeks, J.H., Hopkins, L.N., Cutlip, D.E., Cohen, D.J., Popma, J.J., Ferguson, R.D.,**

- Cohen, S.N., Blackshear, J.L., Silver, F.L., Mohr, J.P., Lal, B.K., Meschia, J.F.; **CREST Investigators**. “Stenting versus endarterectomy for treatment of carotid-artery stenosis.” *N Engl J Med*. 2010 Jul 1;363(1):11-23.
- [20]. Gurm, H.S., Yadav, J.S., Fayad, P., Katzen, B.T., Mishkel, G.J., Bajwa, T.K., Ansel, G., Strickman, N.E., Wang, H., Cohen, S.A., Massaro, J.M., Cutlip, D.E.; **SAPPHIRE Investigators**. “Long-term results of carotid stenting versus endarterectomy in high-risk patients”. *N Engl J Med*. 2008 Apr 10;358(15):1572-9.
- [21]. Eckstein, H.H., Ringleb, P., Allenberg, J.R., Berger, J., Fraedrich, G., Hacke, W., Hennerici, M., Stingele, R., Fiehler, J., Zeumer, H., Jansen, O. “Results of the Stent-Protected Angioplasty versus Carotid Endarterectomy (SPACE) study to treat symptomatic stenoses at 2 years: a multinational, prospective, randomised trial”. *Lancet Neurol*. 2008 Oct;7(10):893-902.
- [22]. Mas, J.L., Trinquart, L., Leys, D., Albucher, J.F., Rousseau, H., Viguier, A., Bossavy, J.P., Denis, B., Piquet, P., Garnier, P., Viader, F., Touzé, E., Julia, P., Giroud, M., Krause, D., Hosseini, H., Becquemin, J.P., Hinzelin, G., Houdart, E., Hénon, H., Neau, J.P., Bracard, S., Onnient, Y., Padovani, R., Chatellier, G.; **EVA-3S investigators**. “Endarterectomy Versus Angioplasty in Patients with Symptomatic Severe Carotid Stenosis (EVA-3S) trial: results up to 4 years from a randomised, multicentre trial”. *Lancet Neurol*. 2008 Oct;7(10):885-92.
- [23]. **Endovascular versus surgical treatment in patients with carotid stenosis in the Carotid and Vertebral Artery Transluminal Angioplasty Study (CAVATAS): a randomised trial**. *Lancet*. 2001 Jun 2;357(9270):1729-37.
- [24]. Brooks, W.H., Jones, M.R., Gisler, P., McClure, R.R., Coleman, T.C., Breathitt, L., Spear, C. “Carotid angioplasty with stenting versus endarterectomy: 10-year randomized trial in a community hospital (Kentucky Study)”. *JACC Cardiovasc Interv*. 2014 Feb;7(2):163-168.
- [25]. Blaisdell, F.W., Lim, R. Jr., Hall, A.D. “Technical result of carotid endarterectomy. Arteriographic assessment”. *Am J Surg*. 1967 Aug;114(2):239-46.
- [26]. Rockman, C.B., Halm, E.A. “Intraoperative imaging: does it really improve perioperative outcomes of carotid endarterectomy?” *Semin Vasc Surg*. 2007 Dec;20(4):236-43.
- [27]. Zannetti, S., Cao, P., De Rango, P., Giordano, G., Parlani, G., Lenti, M., Nora, A. “Intraoperative assessment of technical perfection in carotid endarterectomy: a prospective analysis of 1305 completion procedures. Collaborators of the EVEREST study group. Eversion versus standard carotid endarterectomy”. *Eur J Vasc Endovasc Surg*. 1999 Jul;18(1):52-8.
- [28]. Woelfle, K.D., Bruijnen, H., Neu, J., Campbell, P., Wack, C., Loeprecht, H. “The role of intraoperative digital subtraction angiography for quality control of standard carotid endarterectomy using patch angioplasty”. *Cardiovasc Surg*. 2002 Apr;10(2):116-22.
- [29]. Karnik, R.R., Ammerer, H.P., Winkler, W., Valentin, A.F., & Slany, J. (1994). “Initial experience with intravascular ultrasound imaging during carotid endarterectomy”. *Stroke*, 25 1, 35-9.
- [30]. Sharpe, R., Sayers, R.D., McCarthy, M.J., Dennis, M., London, N.J., Nasim, A., Bown, M.J., Naylor, A.R. “The war against error: a 15 year experience of completion angiography following carotid endarterectomy”. *Eur J Vasc Endovasc Surg*. 2012 Feb;43(2):139-45.
- [31]. Myhre, H.O., Saether, O.D., Mathisen, S.R., Angelsen, B.A.J. “Surgery for Stroke”. 1st ed. Cambridge: The University Press: W. B. Saunders Company LTD; c1993. Colour Coded Duplex Scanning During Carotid Endarterectomy; p. 253-8.
- [32]. Parsa, P., Hodgkiss-Harlow, K., Bandyk, D.F. “Interpretation of intraoperative arterial duplex ultrasound testing”. *Semin Vasc Surg*. 2013 Jun-Sep;26(2-3):105-10.
- [33]. Weinstein, S., Mabray, M.C., Aslam, R., Hope, T., Yee, J., Owens, C. “Intraoperative sonography during carotid endarterectomy: normal appearance and spectrum of complications”. *J Ultrasound Med*. 2015 May;34(5):885-94.
- [34]. Sigel, B., Coelho, J.C., Flanigan, D.P., Schuler, J.J., Spigos, D.G., Machi, J. “Comparison of B-mode real-time ultrasound scanning with arteriography in detecting vascular defects during surgery”. *Radiology*. 1982 Dec;145(3):777-80.

- [35]. **Liapis, C.D., Paraskevas, K.I.** "Role of residual defects following carotid endarterectomy in the occurrence of cerebrovascular symptoms". *Vasc Endovascular Surg.* 2006 Mar-Apr;40(2):119-23.
- [36]. **Burnett, M.G., Stein, S.C., Sonnad, S.S., Zager, E.L.** "Cost-effectiveness of intraoperative imaging in carotid endarterectomy". *Neurosurgery.* 2005 Sep;57(3):478-85; discussion 478-85.
- [37]. **Padayachee, T. S., Brooks, M. D., McGuinness, C. L., Modaresi, K. B., Arnold, J. A., Taylor, P. R.** "Value of intraoperative duplex imaging during supervised carotid endarterectomy". *Br J Surg.* 2001; 88: 389-392.
- [38]. **Liberati, A., Altman, D.G., Tetzlaff, J., Mulrow, C., Gøtzsche, P.C., Ioannidis, J.P., Clarke, M., Devereaux, P.J., Kleijnen, J., Moher, D.** "The PRISMA statement for reporting systematic reviews and meta-analyses of studies that evaluate healthcare interventions: explanation and elaboration". *BMJ.* 2009 Jul 21;339:b2700.
- [39]. **Sigel, B., Flanigan, D.P., Schuler, J.J., Machi, J., Beitler, J.C., Coelho, J.C.** "Imaging ultrasound in the intraoperative diagnosis of vascular defects". *J Ultrasound Med.* 1983 Aug;2(8):337-43.
- [40]. **Zierler, R.E., Bandyk, D.F., Thiele, B.L.** "Intraoperative assessment of carotid endarterectomy". *J Vasc Surg.* 1984 Jan;1(1):73-83.
- [41]. **Seifert, K.B., Blackshear, W.M. Jr.** "Continuous-wave Doppler in the intraoperative assessment of carotid endarterectomy". *J Vasc Surg.* 1985 Nov;2(6):817-20.
- [42]. **Ackroyd, N., Lane, R., Appleberg, M.** "Intraoperative ultrasound during carotid artery surgery". *Aust N Z J Surg.* 1985 Aug;55(4):321-7.
- [43]. **Dilley, R.B. et al.** "A comparison of B-mode real-time imaging and arteriography in the intraoperative assessment of carotid endarterectomy". *J Vasc Surg.* 1986 Nov;4(5):457-463.
- [44]. **Lane, R.J., Ackroyd, N., Appleberg, M., Graham, J.** "The application of operative ultrasound immediately following carotid endarterectomy". *World J Surg.* 1987 Oct;11(5):593-7.
- [45]. **Schwartz, R.A., Peterson, G.J., Noland, K.A., Hower, J.F. Jr., Naunheim, K.S.** "Intraoperative duplex scanning after carotid artery reconstruction: a valuable tool". *J Vasc Surg.* 1988 May;7(5):620-4.
- [46]. **Sawchuk, A.P., Flanigan, D.P., Machi, J., Schuler, J.J., Sigel, B.** "The fate of unrepaired minor technical defects detected by intraoperative ultrasonography during carotid endarterectomy". *J Vasc Surg.* 1989 May;9(5):671-5; discussion 675-6.
- [47]. **Kinney, E.V., Seabrook, G.R., Kinney, L.Y., Bandyk, D.F., Towne, J.B.** "The importance of intraoperative detection of residual flow abnormalities after carotid artery endarterectomy." *J Vasc Surg.* 1993 May;17(5):912-22; discussion 922-3.
- [48]. **Bandyk, D.F., Mills, J.L., Gahtan, V., Esses, G.E.** "Intraoperative duplex scanning of arterial reconstructions: fate of repaired and unrepaired defects". *J Vasc Surg.* 1994 Sep;20(3):426-32; discussion 432-3.
- [49]. **Hoff, C., de Gier, P., Buth, J.** "Intraoperative duplex monitoring of the carotid bifurcation for the detection of technical defects". *Eur J Vasc Surg.* 1994 Jul;8(4):441-7.
- [50]. **Lingenfelter, K.A., Fuller, B.C., Sullivan, T.M.** "Intraoperative assessment of carotid endarterectomy: a comparison of techniques". *Ann Vasc Surg.* 1995 May;9(3):235-40.
- [51]. **Lipski, D.A., Bergamini, T.M., Garrison, R.N., Fulton, R.L.** "Intraoperative duplex scanning reduces the incidence of residual stenosis after carotid endarterectomy". *J Surg Res.* 1996 Feb 1;60(2):317-20.
- [52]. **Papanicolaou, G., Toms, C., Yellin, A.E., Weaver, F.A.** "Relationship between intraoperative color-flow duplex findings and early restenosis after carotid endarterectomy: a preliminary report". *J Vasc Surg.* 1996 Oct;24(4):588-95; discussion 595-6.
- [53]. **Gaunt, M.E., Smith, J.L., Ratliff, D.A., Bell P.R., Naylor, A.R.** "A comparison of quality control methods applied to carotid endarterectomy". *Eur J Vasc Endovasc Surg.* 1996 Jan;11(1):4-11.
- [54]. **Dorffner, R., Metz, V.M., Trattng, S., Eibenberger, K., Dock, W., Hörmann, M., Trubel, W., Grabenwöger, F.** "Intraoperative and early postoperative colour Doppler sonography after carotid artery reconstruction: follow-up of technical defects". *Neuroradiology.* 1997 Feb;39(2):117-21.

- [55]. **Steinmetz, O.K., MacKenzie, K., Nault, P., Singher, F., Dumaine, J.** "Intraoperative duplex scanning for carotid endarterectomy". *Eur J Vasc Endovasc Surg.* 1998 Aug;16(2):153-8.
- [56]. **Roth, S.M., Back, M.R., Bandyk, D.F., Avino, A.J., Riley, V., Johnson, B.L.** "A rational algorithm for duplex scan surveillance after carotid endarterectomy". *J Vasc Surg.* 1999 Sep;30(3):453-60.
- [57]. **Mansour, M.A., Webb, K.M., Kang, S.S., Labropoulos, N., Littooy, F.N., Greisler, H.P., Baker, W.H.** "Timing and frequency of perioperative carotid color-flow duplex scanning: A preliminary report". *J Vasc Surg.* 1999 May;29(5):833-7.
- [58]. **Walker, R. A., Walker, E. A., McCabe, A., Horrocks, E., Budd, J.S., Horrocks, M.** "Re-evaluation of criteria for reoperation in carotid endarterectomy using intraoperative duplex imaging". *Br J Surg.* 1999 86: 691-692.
- [59]. **Seelig, M.H., Oldenburg, W.A., Chowla, A., Atkinson, E.J.** "Use of intraoperative duplex ultrasonography and routine patch angioplasty in patients undergoing carotid endarterectomy". *Mayo Clin Proc.* 1999 Sep;74(9):870-6. Erratum in: *Mayo Clin Proc* 1999 Oct;74(10):1056.
- [60]. **Mays, B.W., Towne, J.B., Seabrook, G.R., Cambria, R.A., Jean-Claude, J.** "Intraoperative carotid evaluation". *Arch Surg.* 2000 May;135(5):525-8; discussion 528-9.
- [61]. **Pross, C., Shortsleeve, C.M., Baker, J.D., Sicklick, J.K., Farooq, M.M., Moore, W.S., Quiñones-Baldrich, W.J., Ahn, S.S., Gelabert, H.A., Freischlag, J.A.** "Carotid endarterectomy with normal findings from a completion study: Is there need for early duplex scan?". *J Vasc Surg.* 2001 May;33(5):963-7.
- [62]. **Krug, R.T., Calligaro, K.D., Dougherty, M.J., Raviola, C.A.** "Comparison of intraoperative and postoperative duplex ultrasound for carotid endarterectomy". *Ann Vasc Surg.* 2001 Nov;15(6):666-8.
- [63]. **Panneton, J.M., Berger, M.W., Lewis, B.D., Hallett, J.W. Jr., Bower, T.C., Gloviczki, P., Cherry, K.J. Jr.** "Intraoperative duplex ultrasound during carotid endarterectomy". *Vasc Surg.* 2001 Jan-Feb;35(1):1-9.
- [64]. **Padayachee, T.S., Arnold, J.A., Thomas, N., Aukett, M., Colchester, A.C., Taylor, P.R.** "Correlation of intra-operative duplex findings during carotid endarterectomy with neurological events and recurrent stenosis at one year". *Eur J Vasc Endovasc Surg.* 2002 Nov;24(5):435-9.
- [65]. **Mullenix, P.S., Tollefson, D.F., Olsen, S.B., Hadro, N.C., Andersen, C.A.** "Intraoperative duplex ultrasonography as an adjunct to technical excellence in 100 consecutive carotid endarterectomies". *Am J Surg.* 2003 May;185(5):445-9.
- [66]. **Valenti, D., Gaggiano, A., Berardi, G., Ferri, M., Mazzei, R., Roda, G., Palombo, D.** "Intra-operative assessment of technical defects after carotid endarterectomy: a comparison between angiography and colour duplex scan". *Cardiovasc Surg.* 2003 Feb;11(1):26-9.
- [67]. **Ascher, E., Markevich, N., Kallakuri, S., Schutzer, R.W., Hingorani, A.P.** "Intraoperative carotid artery duplex scanning in a modern series of 650 consecutive primary endarterectomy procedures". *J Vasc Surg.* 2004 Feb;39(2):416-20.
- [68]. **Winkler, G.A., Calligaro, K.D., Kolakowski, S., Doerr, K.J., McAfee-Bennett, S., Muller, K., Dougherty, M.J.** "Comparison of intraoperative completion flowmeter versus duplex ultrasonography and contrast arteriography for carotid endarterectomy". *Vasc Endovascular Surg.* 2006 Dec-2007 Jan;40(6):482-6.
- [69]. **Yuan, J.Y., Durward, Q.J., Pary, J.K., Vasgaard, J.E., Coggins, P.K.** "Use of intraoperative duplex ultrasonography for identification and patch repair of kinking stenosis after carotid endarterectomy: a single-surgeon retrospective experience". *World Neurosurg.* 2014 Feb;81(2):334-4.
- [70]. **Zierler, R.E., Bandyk, D.F., Berni, G.A., Thiele, B.L.** "Intraoperative pulsed Doppler assessment of carotid endarterectomy". *Ultrasound Med Biol.* 1983 Jan-Feb;9(1):65-71.
- [71]. **Lane, R.J., Appleberg, M.** "Real-time intraoperative angiosonography after carotid endarterectomy". *Surgery.* 1982 Jul;92(1):5-9.
- [72]. **Baker, W.H., Koustas, G., Burke, K., Littooy, F.N., Greisler, H.P.** "Intraoperative duplex scanning and late carotid artery stenosis". *J Vasc Surg.* 1994 May;19(5):829-32; discussion 832-3.

- [73]. **Walker, R.A., Fox, A.D., Magee, T.R., Horrocks, M.** “Intraoperative duplex scanning as a means of quality control during carotid endarterectomy”. *Eur J Vasc Endovasc Surg.* 1996 Apr;11(3):364-7.
- [74]. **Padayachee, T.S., Brooks, M.D., Modaresi, K.B., Arnold, A.J., Self, G.W., Taylor, P.R.** “Intraoperative high resolution duplex imaging during carotid endarterectomy: which abnormalities require surgical correction?” *Eur J Vasc Endovasc Surg.* 1998 May;15(5):387-93.
- [75]. **Padayachee, T.S., Taylor, P.R.** “Intraoperative duplex imaging of carotid endarterectomy”. *Eur J Vasc Endovasc Surg.* 1999 Jun;17(6):465-7.
- [76]. **Ascher, E., Markevich, N., Hingorani, A.P., Kallakuri, S., Gunduz, Y.** “Internal carotid artery flow volume measurement and other intraoperative duplex scanning parameters as predictors of stroke after carotid endarterectomy”. *J Vasc Surg.* 2002 Mar;35(3):439-44.
- [77]. **Liapis, C.D., Bell, P.R., Mikhailidis, D., Sivenius, J., Nicolaidis, A., Fernandes e Fernandes, J., Biasi, G., Norgren, L.; ESVS Guidelines Collaborators.** “ESVS guidelines. Invasive treatment for carotid stenosis: indications, techniques”. *Eur J Vasc Endovasc Surg.* 2009 Apr;37(4 Suppl):1-19.
- [78]. **Ricotta, J.J., Aburahma, A., Ascher, E., Eskandari, M., Faries, P., Lal, B.K.; Society for Vascular Surgery.** “Updated Society for Vascular Surgery guidelines for management of extracranial carotid disease”. *J Vasc Surg.* 2011 Sep;54(3):e1-31.
- [79]. **Naylor, A.R., Ricco, J.B., de Borst, G.J., Debus, S., de Haro, J., Halliday, A., Hamilton, G., Kakisis, J., Kakkos, S., Lepidi, S., Markus, H.S., McCabe, D.J., Roy, J., Sillesen, H., van den Berg, J.C., Vermassen, F., ESVS Guidelines Committee, Kolh, P., Chakfe, N., Hincliffe, R.J., Koncar, I., Lindholt, J.S., Vega de Ceniga, M., Verzini, F., ESVS Guideline Reviewers, Archie, J., Bellmunt, S., Chaudhuri, A., Koelemay, M., Lindahl, A.K., Padberg, F., Venermo, M.** “Editor's Choice - Management of Atherosclerotic Carotid and Vertebral Artery Disease: 2017 Clinical Practice Guidelines of the European Society for Vascular Surgery (ESVS)”. *Eur J Vasc Endovasc Surg.* 2018 Jan;55(1):3-81.
- [80]. **Orrapin, S., Rerkasem, K.** “Carotid endarterectomy for symptomatic carotid stenosis”. *Cochrane Database Syst Rev.* 2017 Jun 7;6:CD001081.
- [81]. **Chambers, B.R., Donnan, G.A.** “Carotid endarterectomy for asymptomatic carotid stenosis”. *Cochrane Database Syst Rev.* 2005 Oct19;(4):CD001923.
- [82]. **Biller, J., Feinberg, W.M., Castaldo, J.E., et al.** “Guidelines for carotid endarterectomy: a statement for healthcare professionals from a Special Writing Group of the Stroke Council, American Heart Association”. *Circulation* 1998; 97:501.
- [83]. **Beach, K.W., Bergelin, R.O., Leotta, D.F., et al.** “Standardized ultrasound evaluation of carotid stenosis for clinical trials: University of Washington Ultrasound Reading Center”. *Cardiovasc Ultrasound.* 2010;8:39. Published 2010 Sep 7.
- [84]. **Wallaert, J.B., Goodney, P.P., Vignati, J.J., Stone, D.H., Nolan, B.W., Bertges, D.J., Walsh, D.B., Cronenwett, J.L.** “Completion imaging after carotid endarterectomy in the Vascular Study Group of New England”. *J Vasc Surg.* 2011 Aug;54(2):376-85, 385.e1-3.
- [85]. **Halm, E.A., Hannan, E.L., Rojas, M., Tuhim, S., Riles, T.S., Rockman, C.B., Chassin, M.R.** “Clinical and operative predictors of outcomes of carotid endarterectomy”. *J Vasc Surg.* 2005 Sep;42(3):420-8.
- [86]. **Ricco, J.B., Schneider, F., Illuminati, G.** “Part one: for the motion. Completion angiography should be used routinely following carotid endarterectomy”. *Eur J Vasc Endovasc Surg.* 2013 May;45(5):416-9.
- [87]. **Samson, R.H.** “Part two: against the motion. Completion angiography is unnecessary following carotid endarterectomy”. *Eur J Vasc Endovasc Surg.* 2013 May;45(5):420-2.